6. BIOPTICKÝ DEŇ

MEDIREX GROUP a SSP

Bratislava 2017

# Prípad SD-IAP č. 625

**Ľ. Straka**

# ALPHA MEDICAL

straka.lubomir@alphamedical.sk

# Prípad SD-IAP č. 625

- 65 ročný pacient
- 1 rok rastúci, prominujúci tumorózny útvar na koreni jazyka hladkého povrchu, veľkosti 10 x10 mm
- Ovoidné šedé tkanivo s časťou priliehajúcej sliznice, 18 x 10 x 12 mm

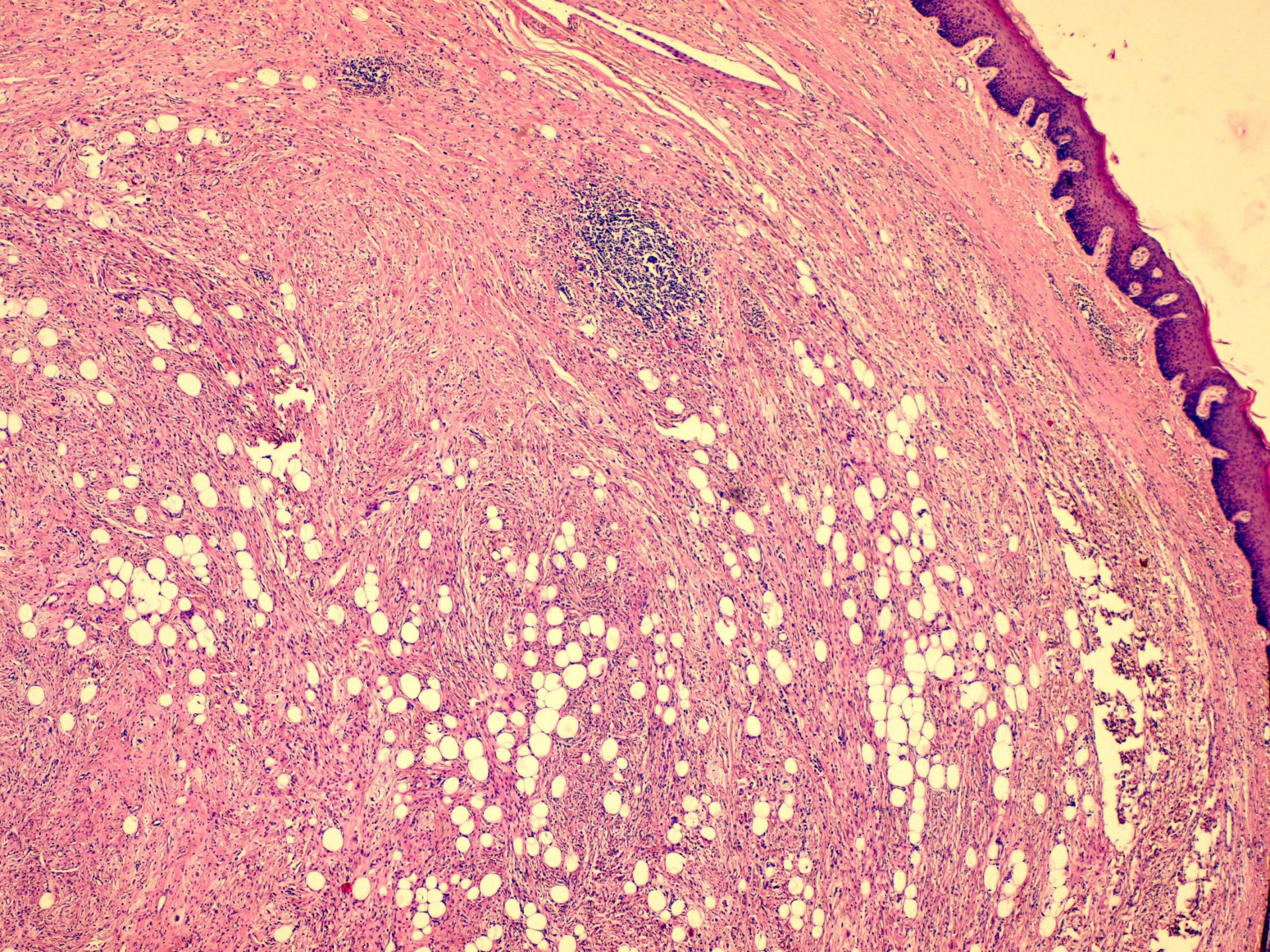

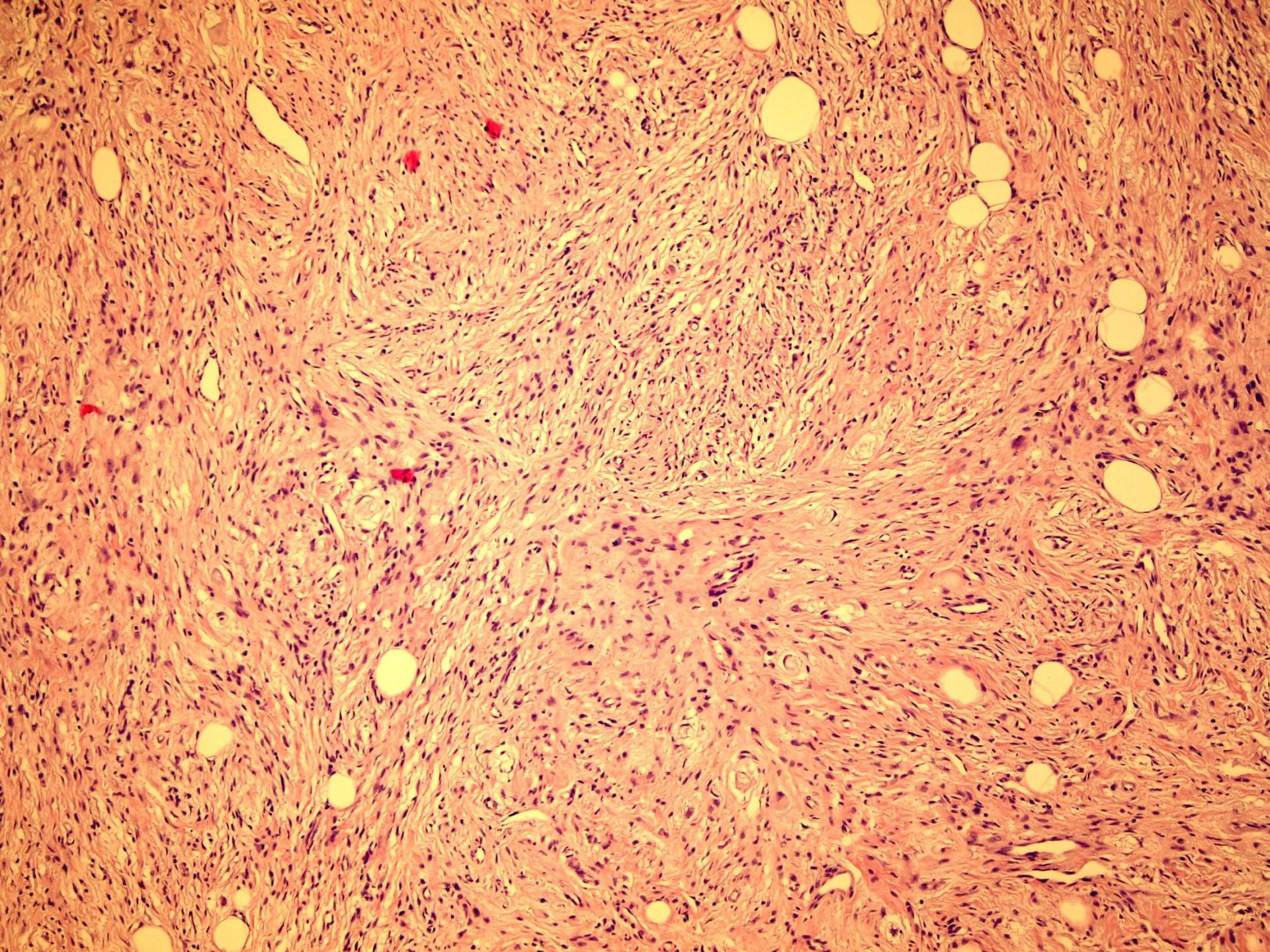

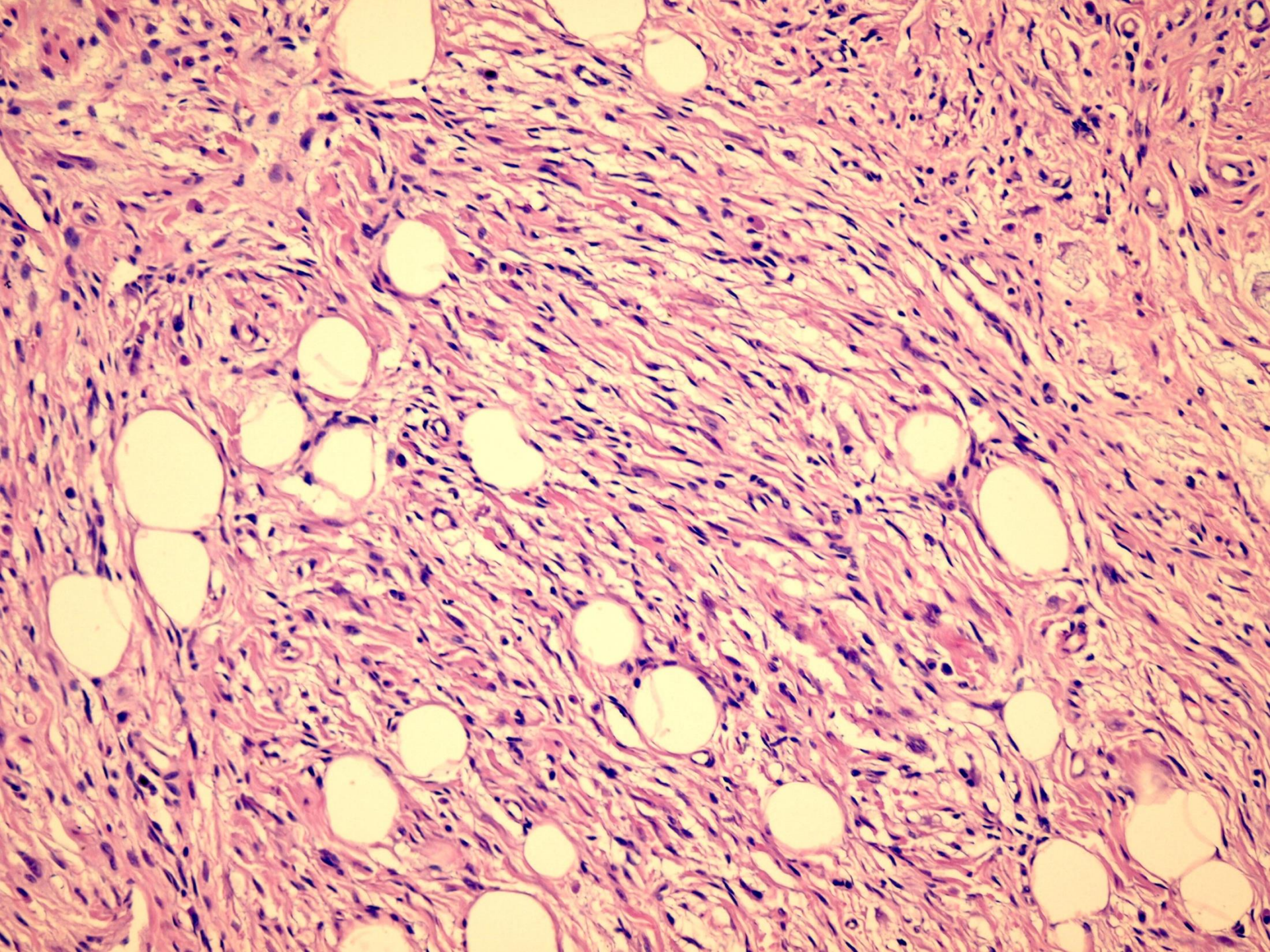

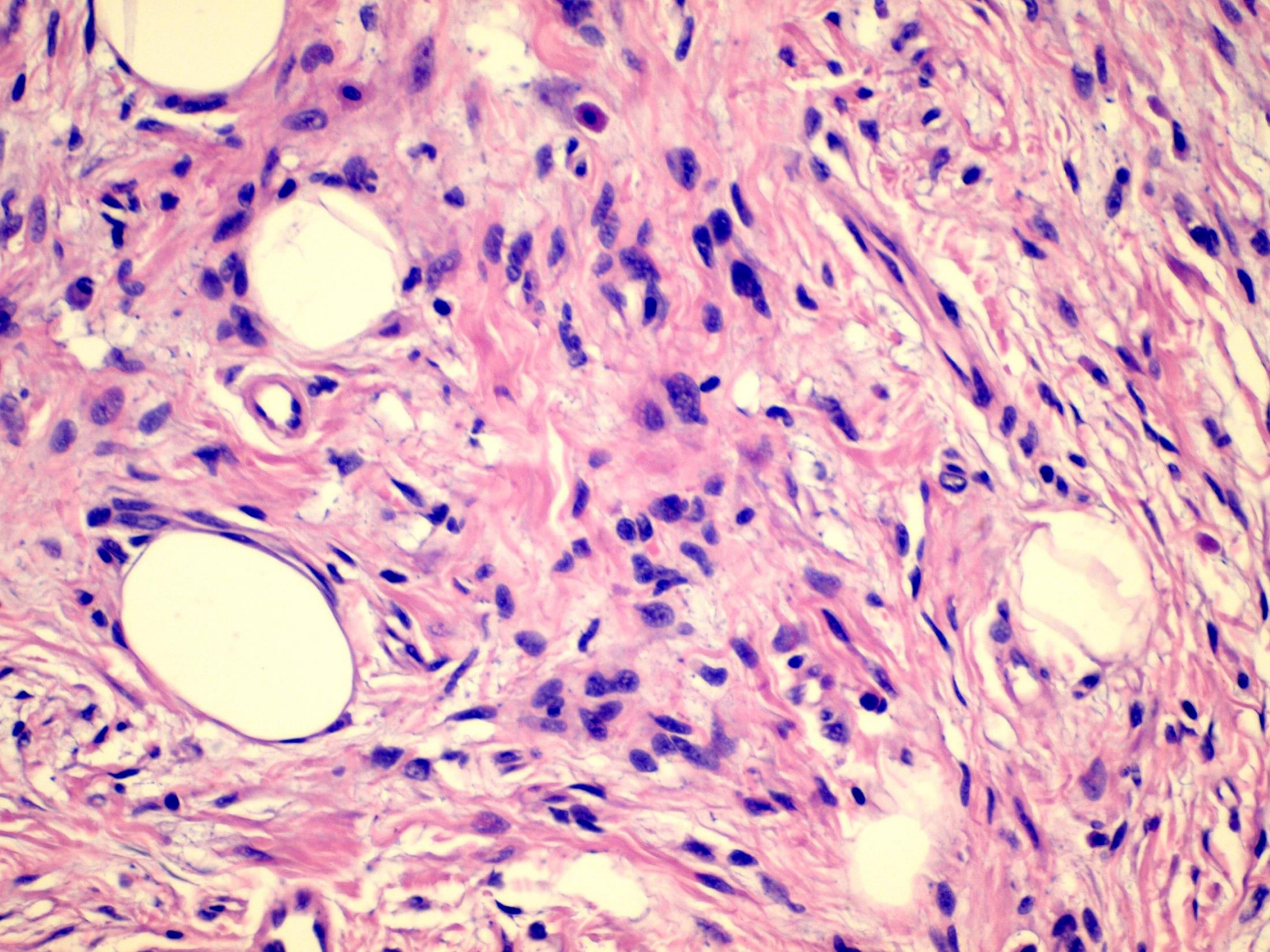

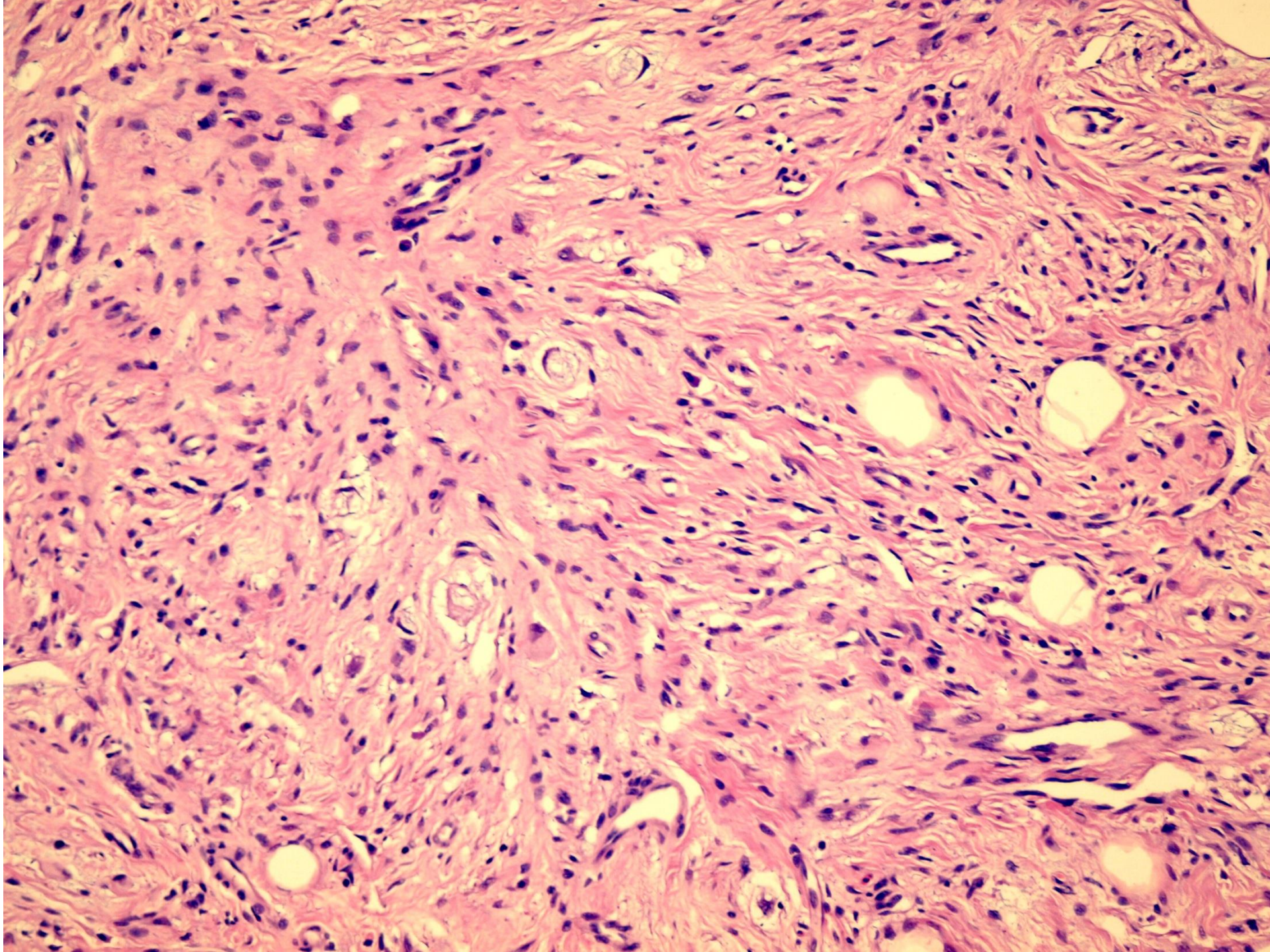

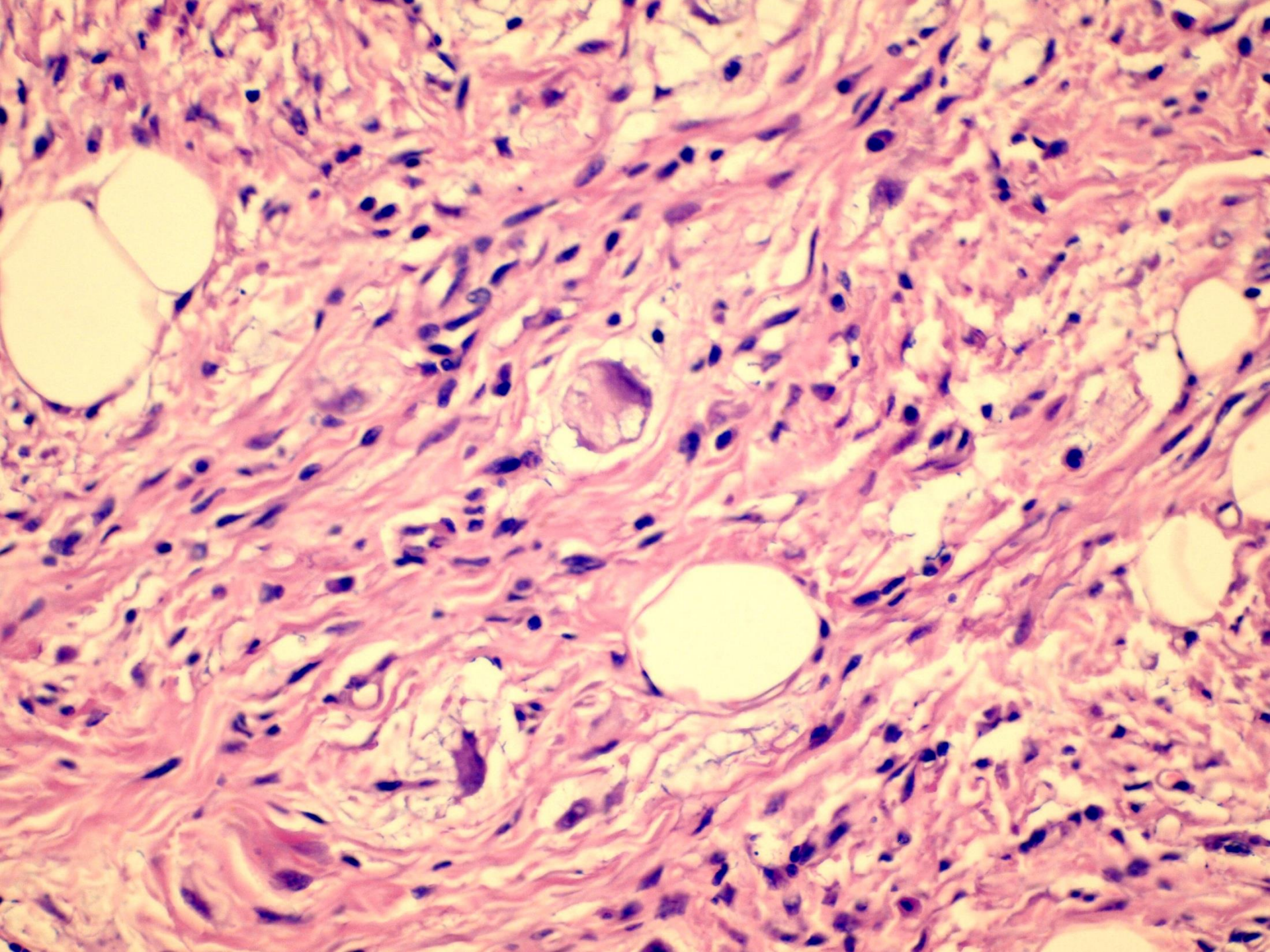

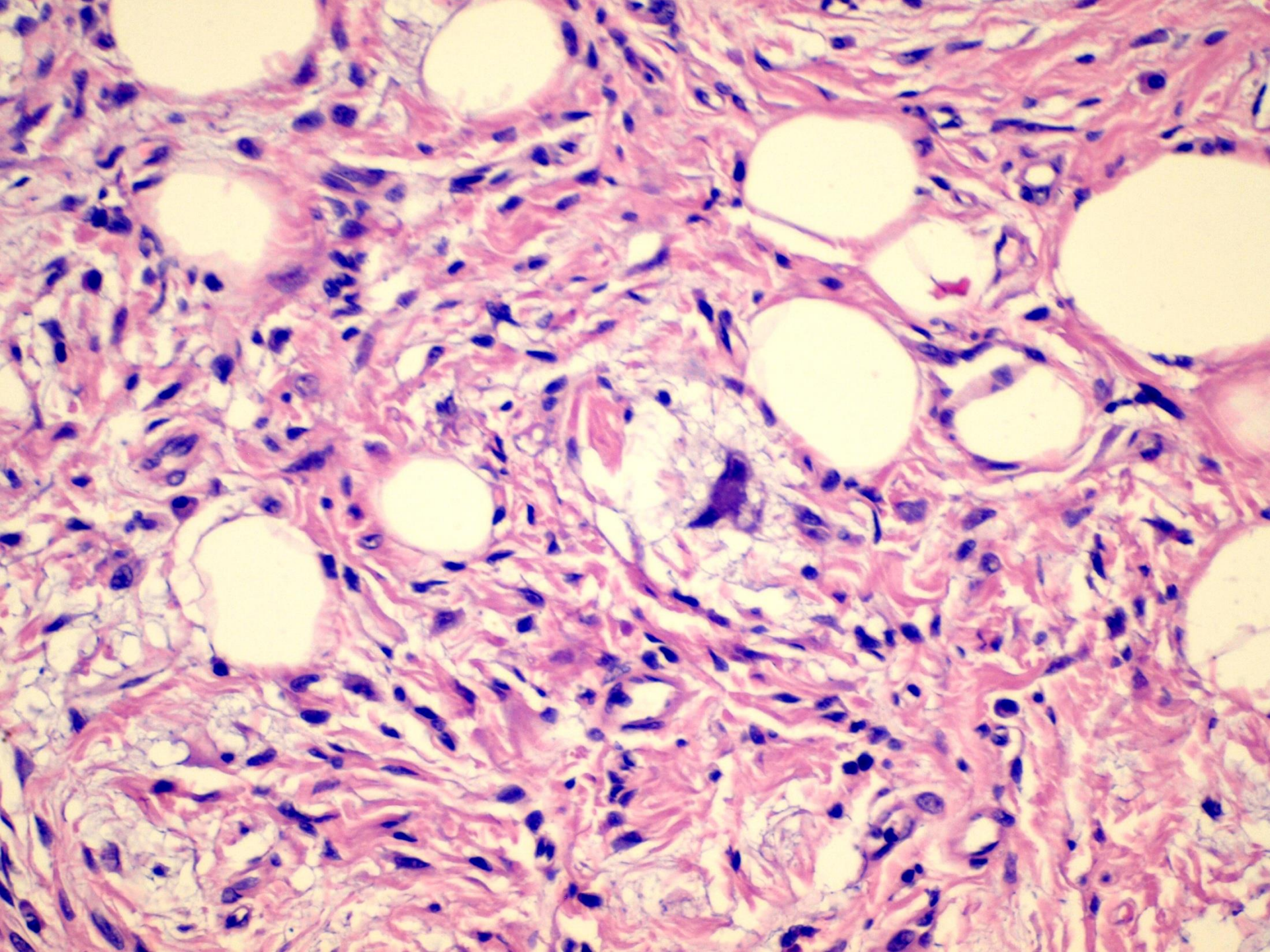

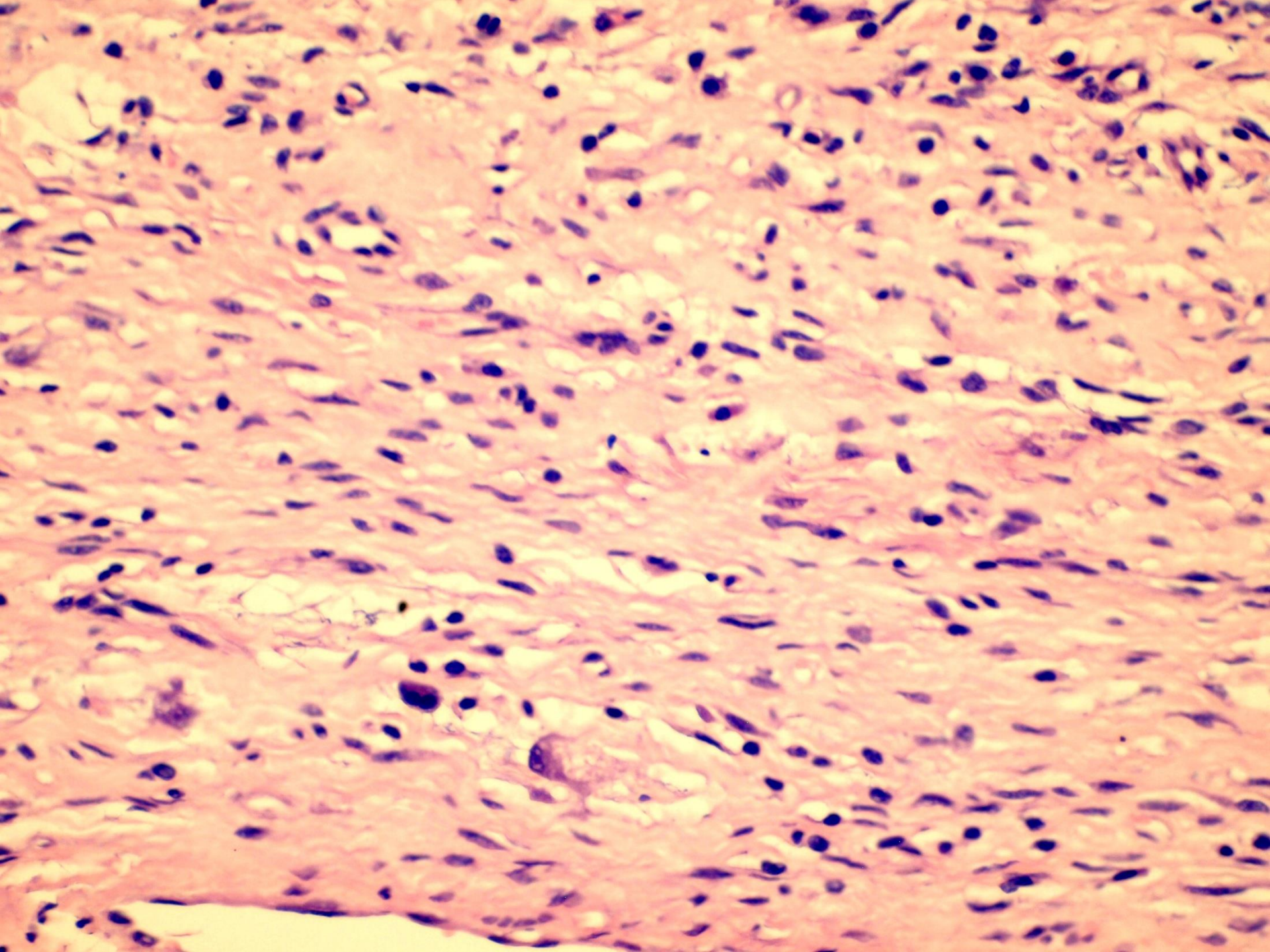

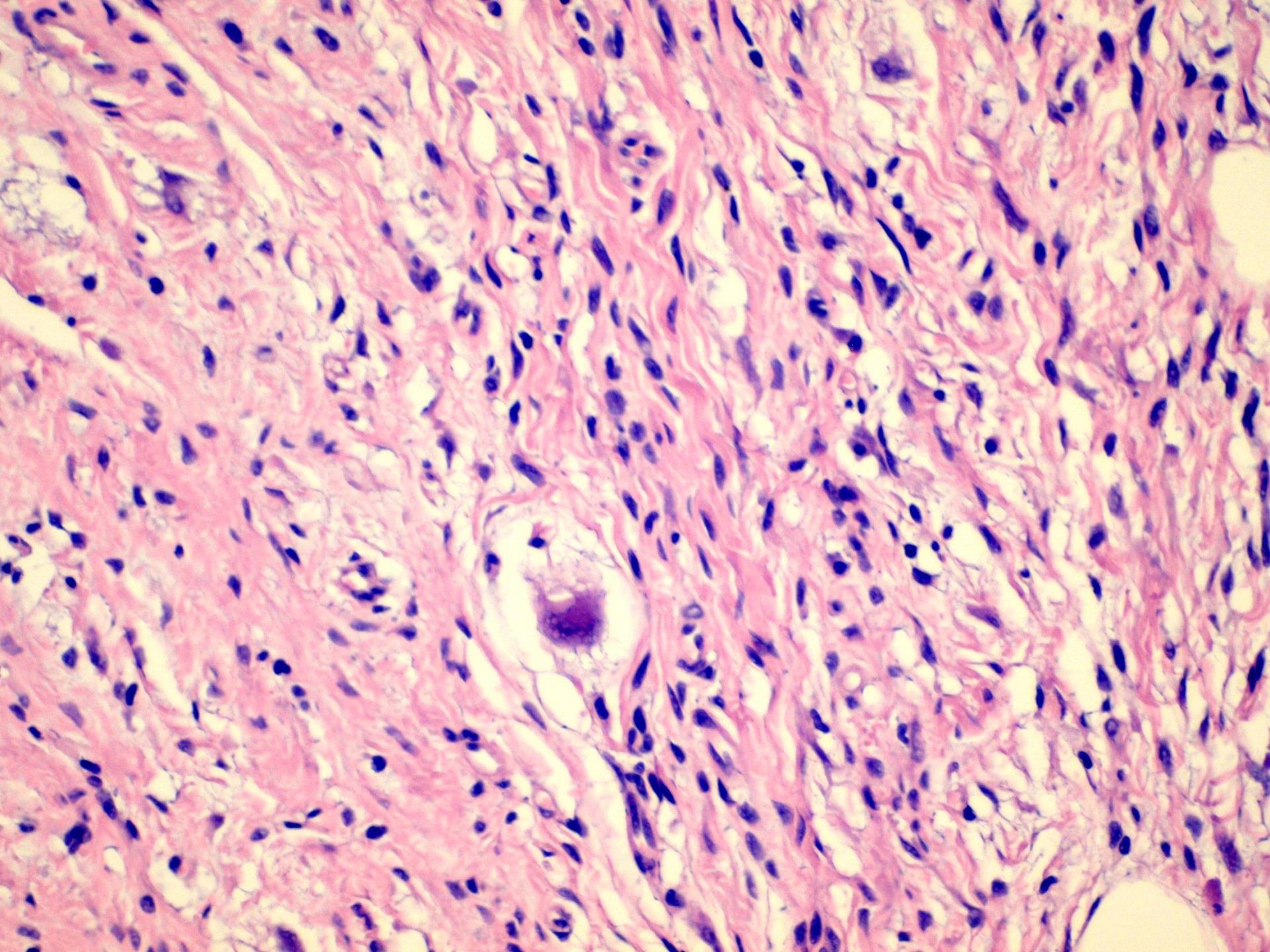

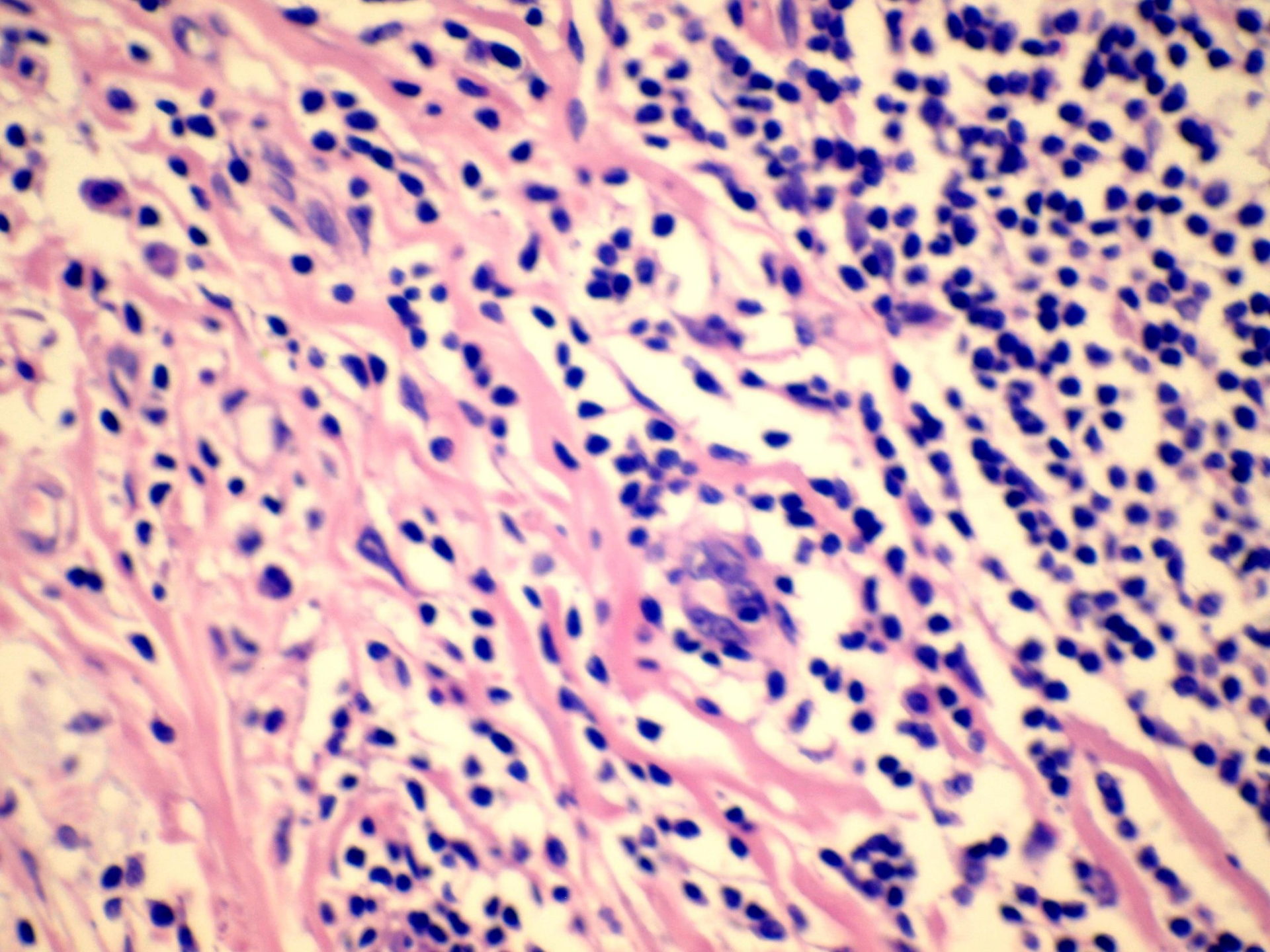

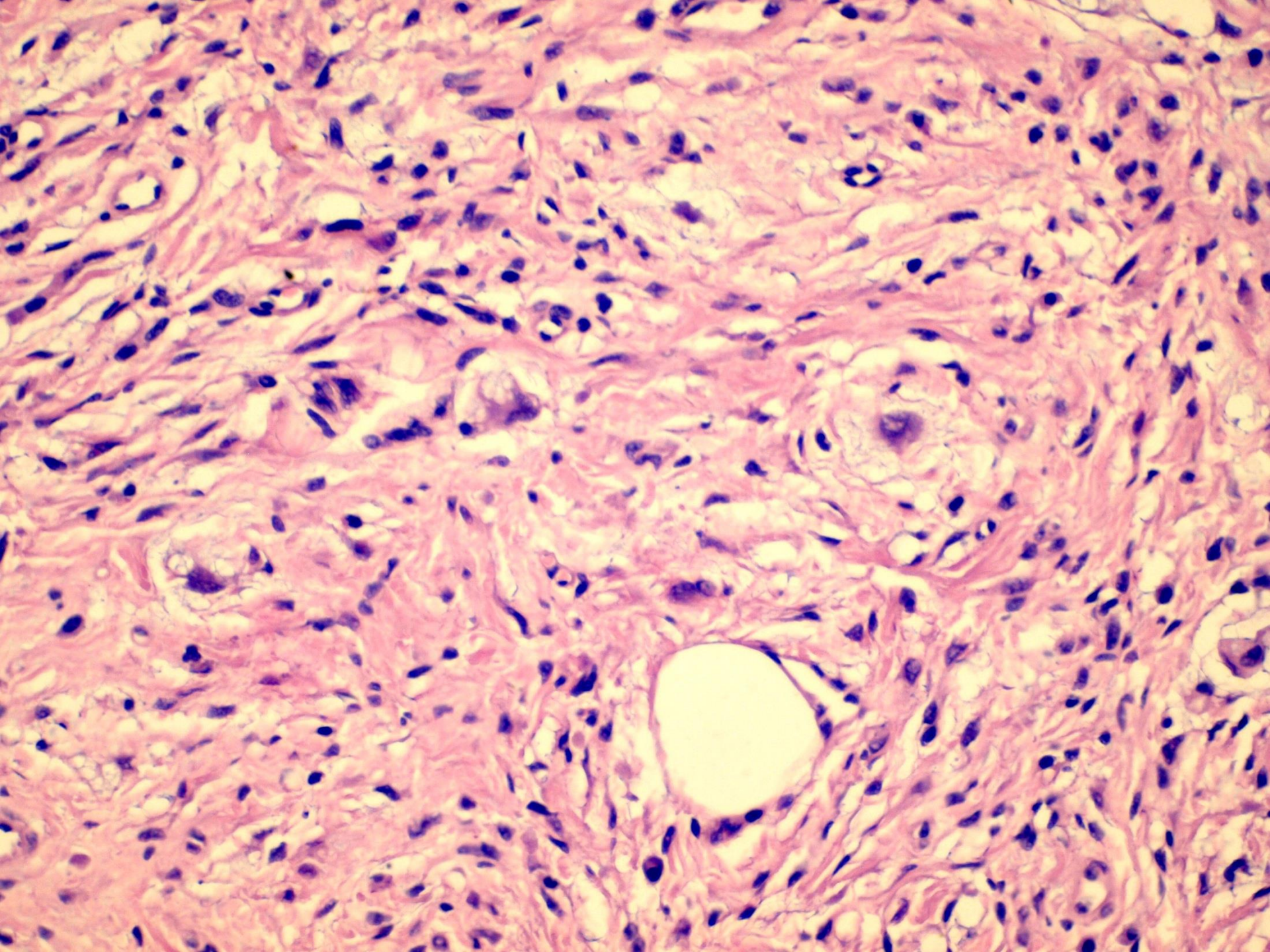

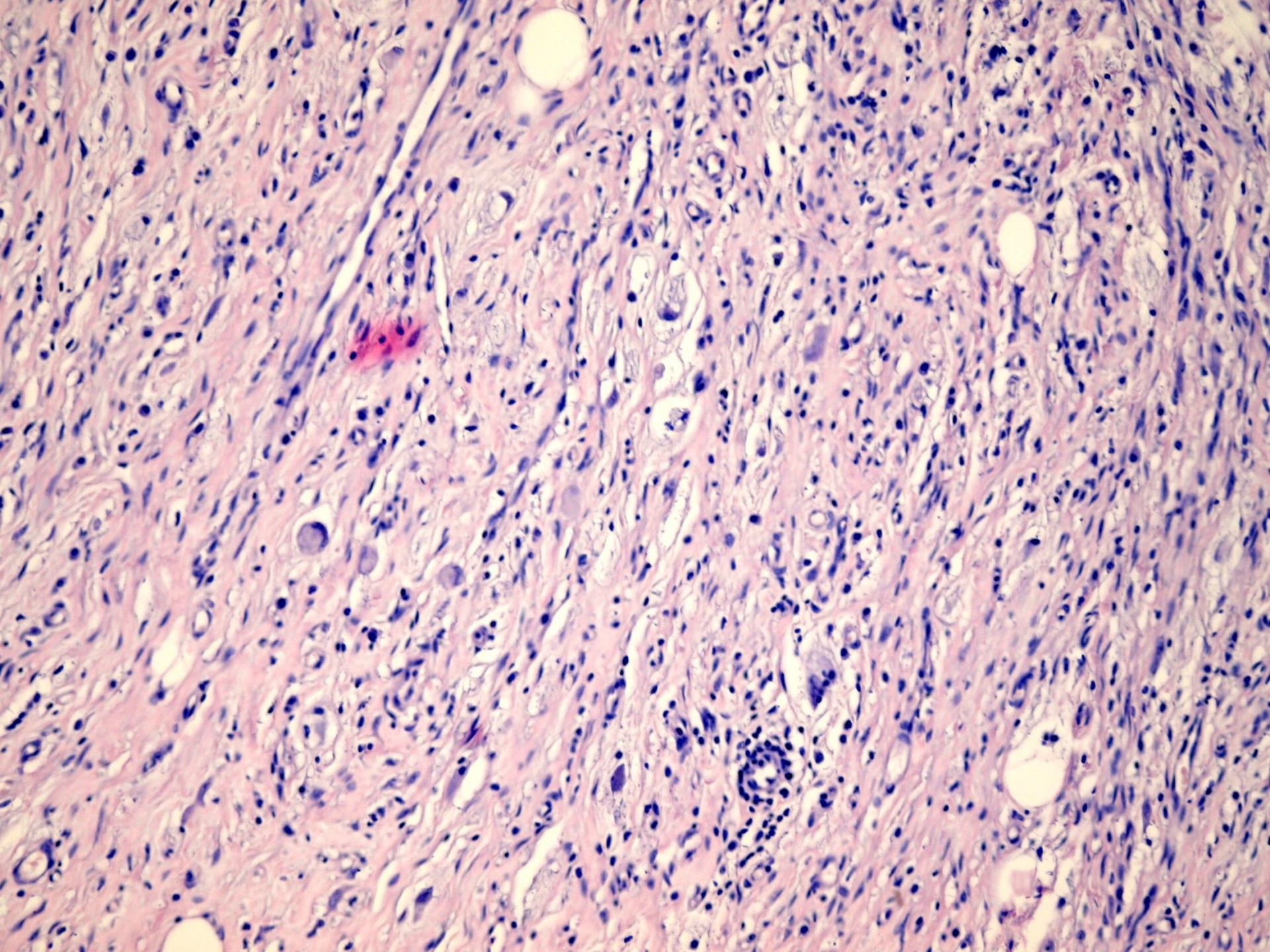

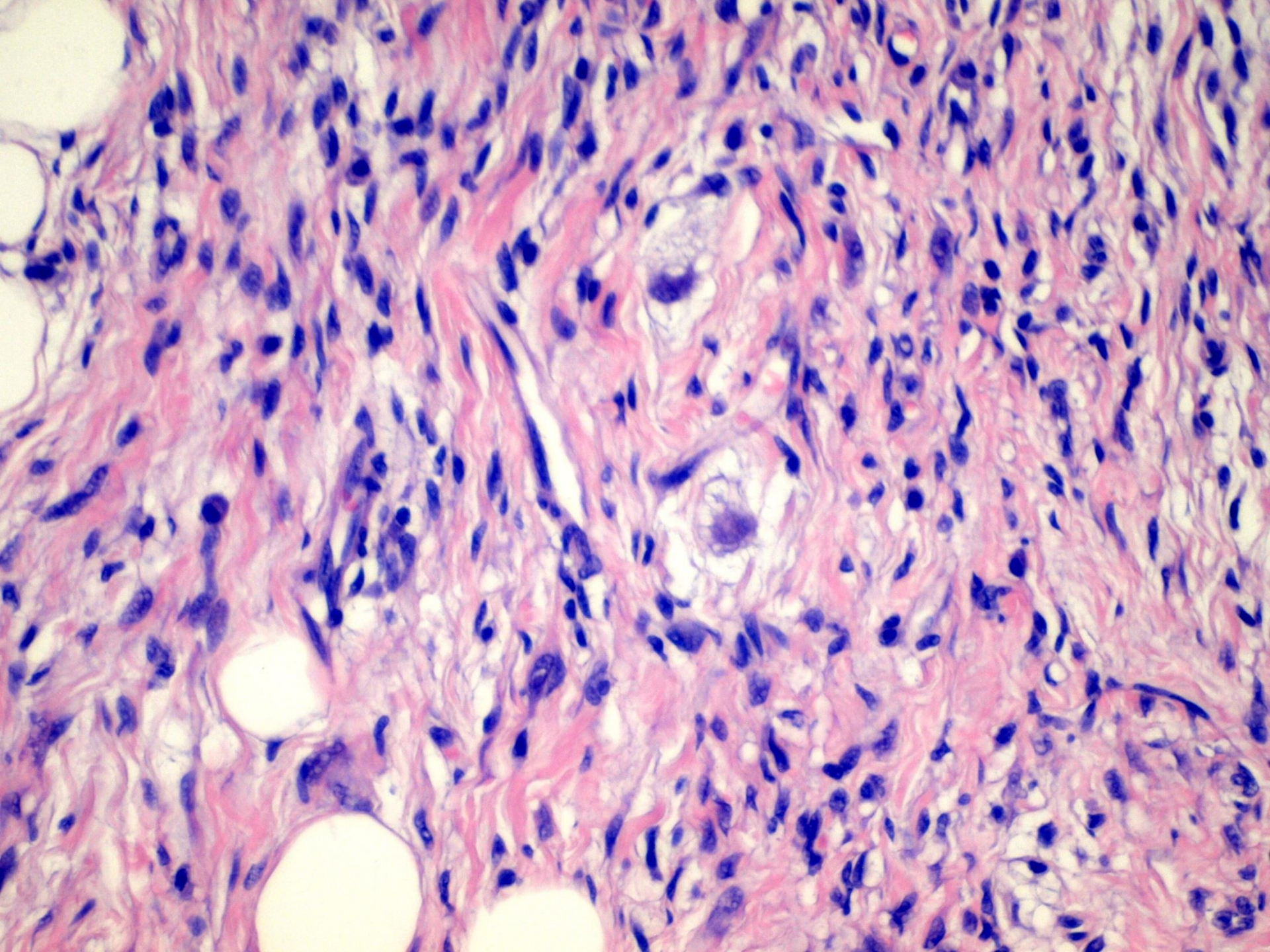

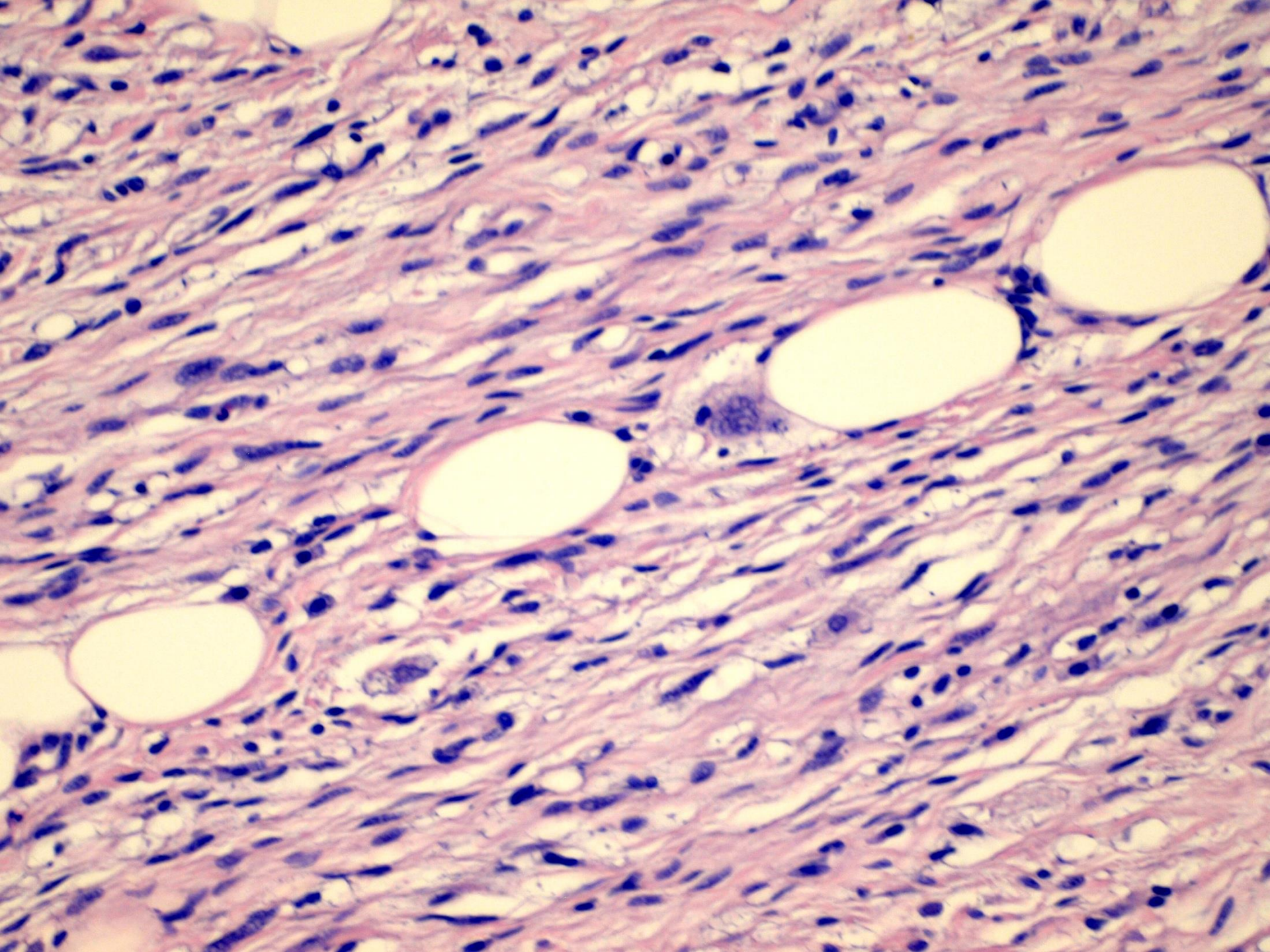

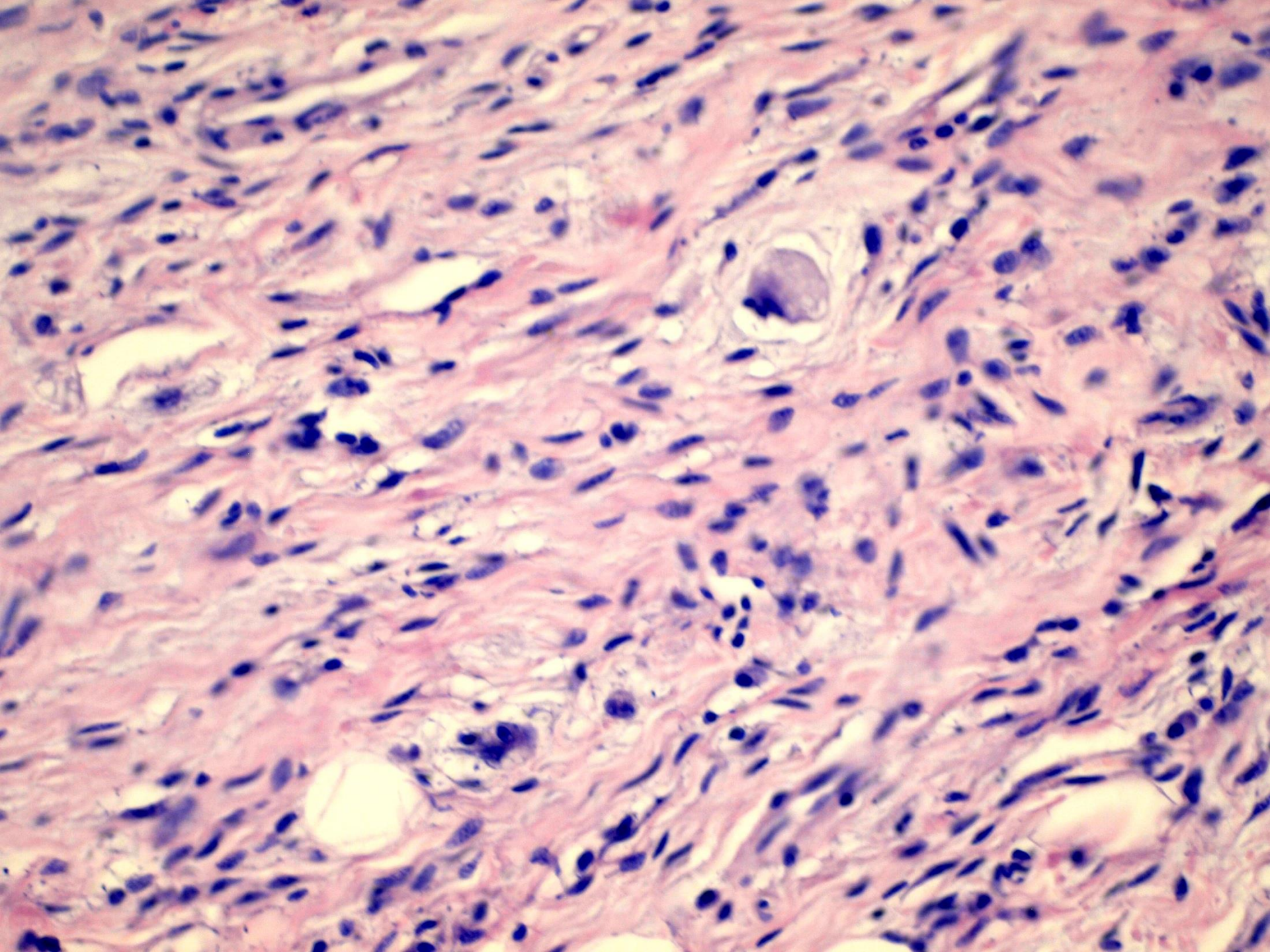

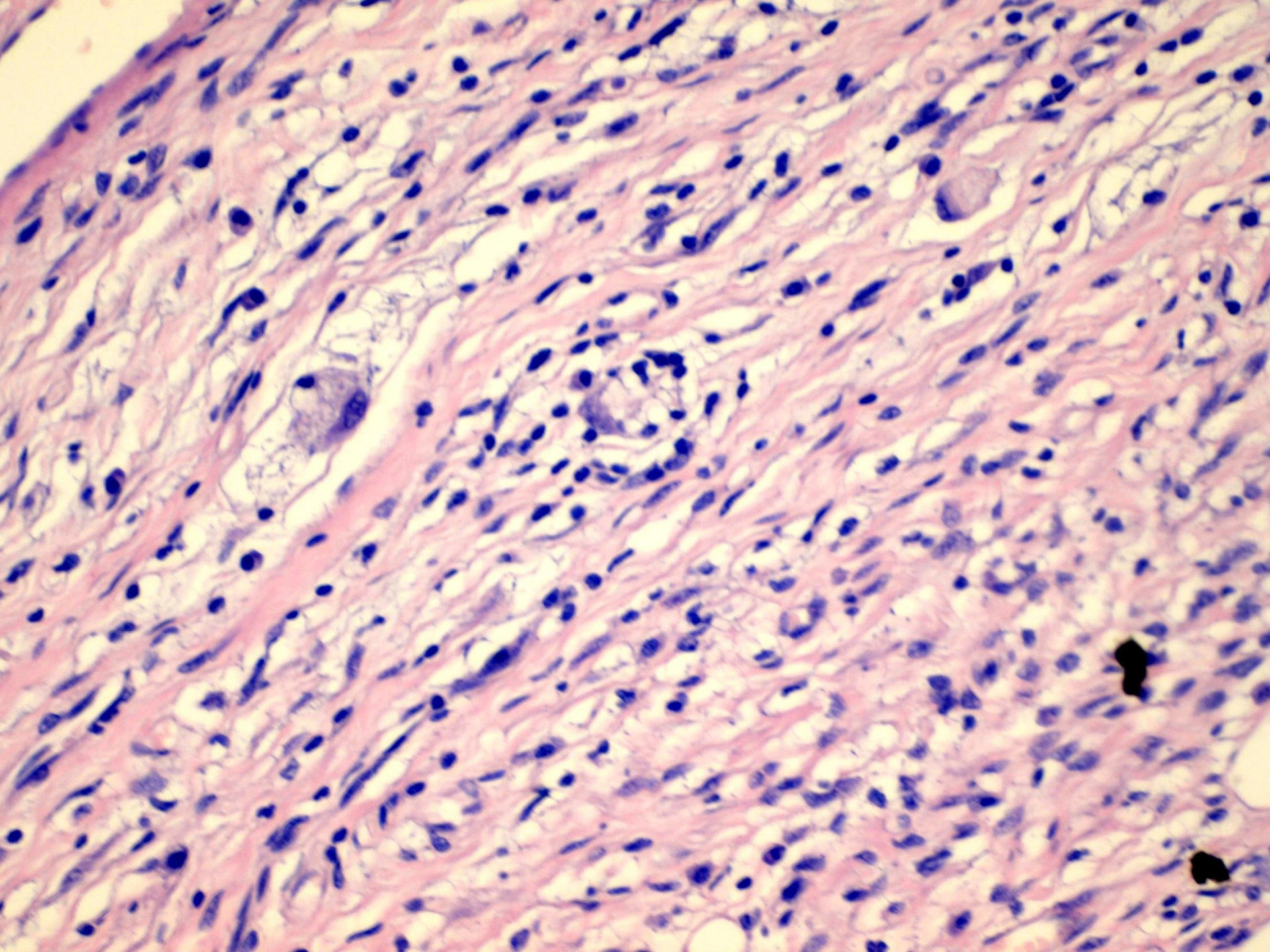

?

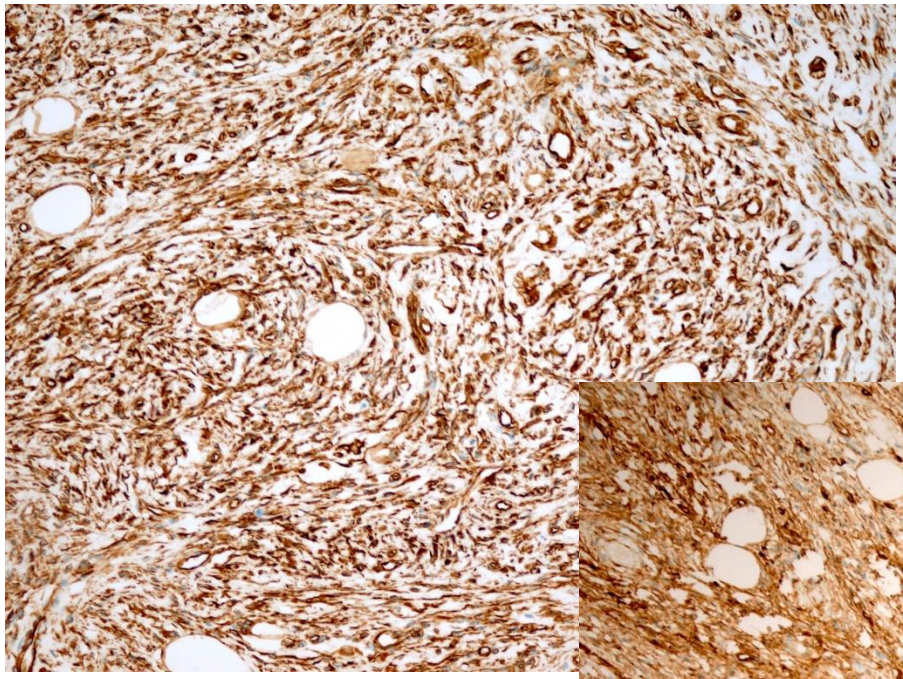

Vimentin

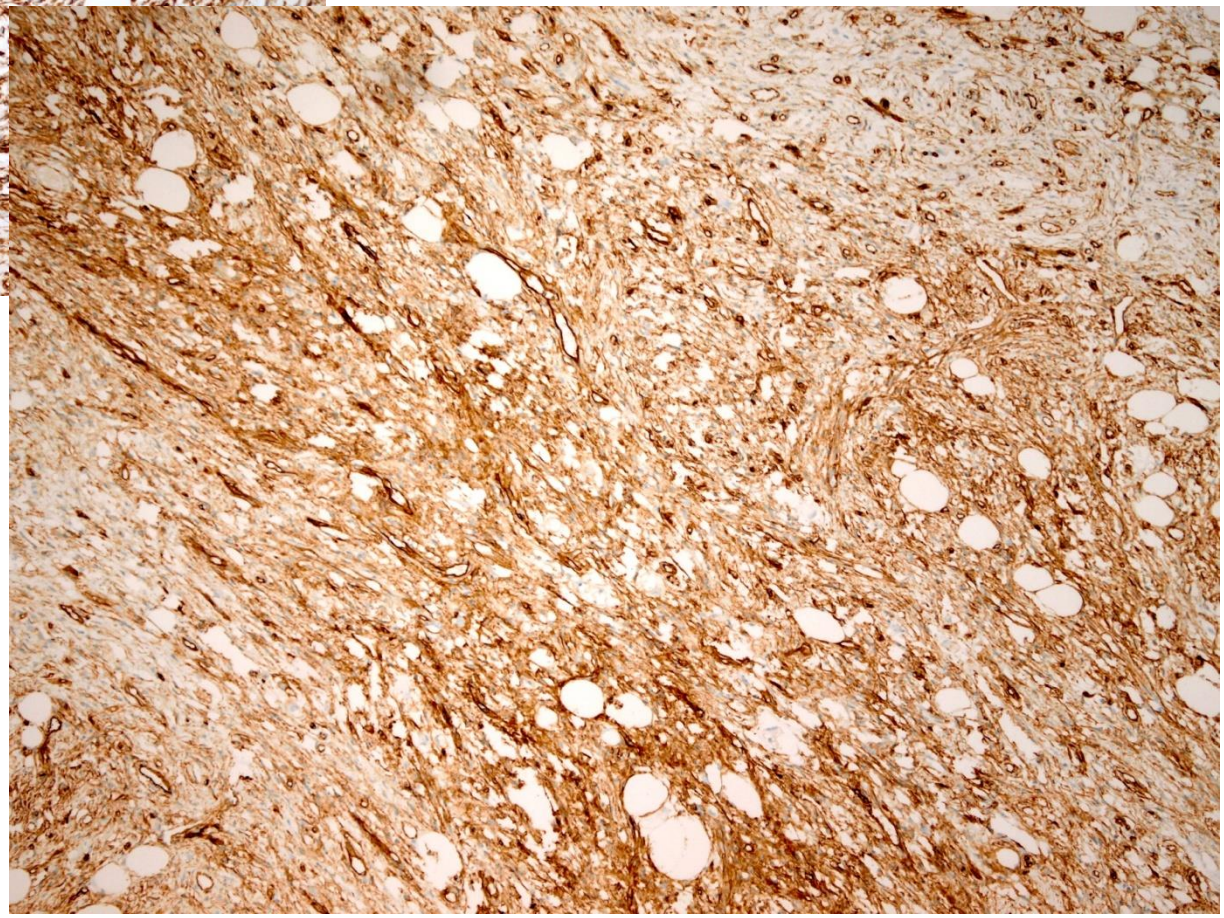

CD34

# EMA

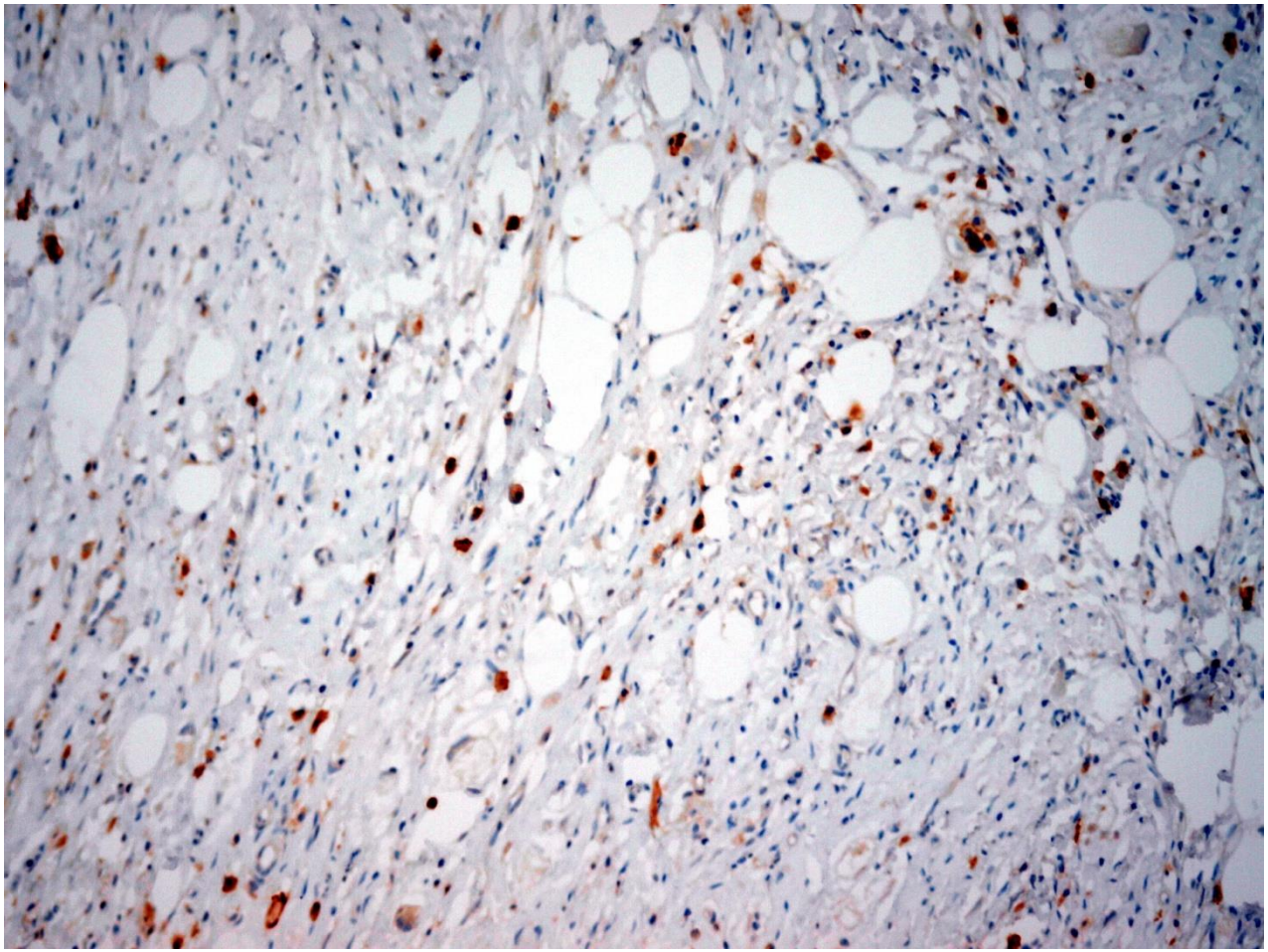

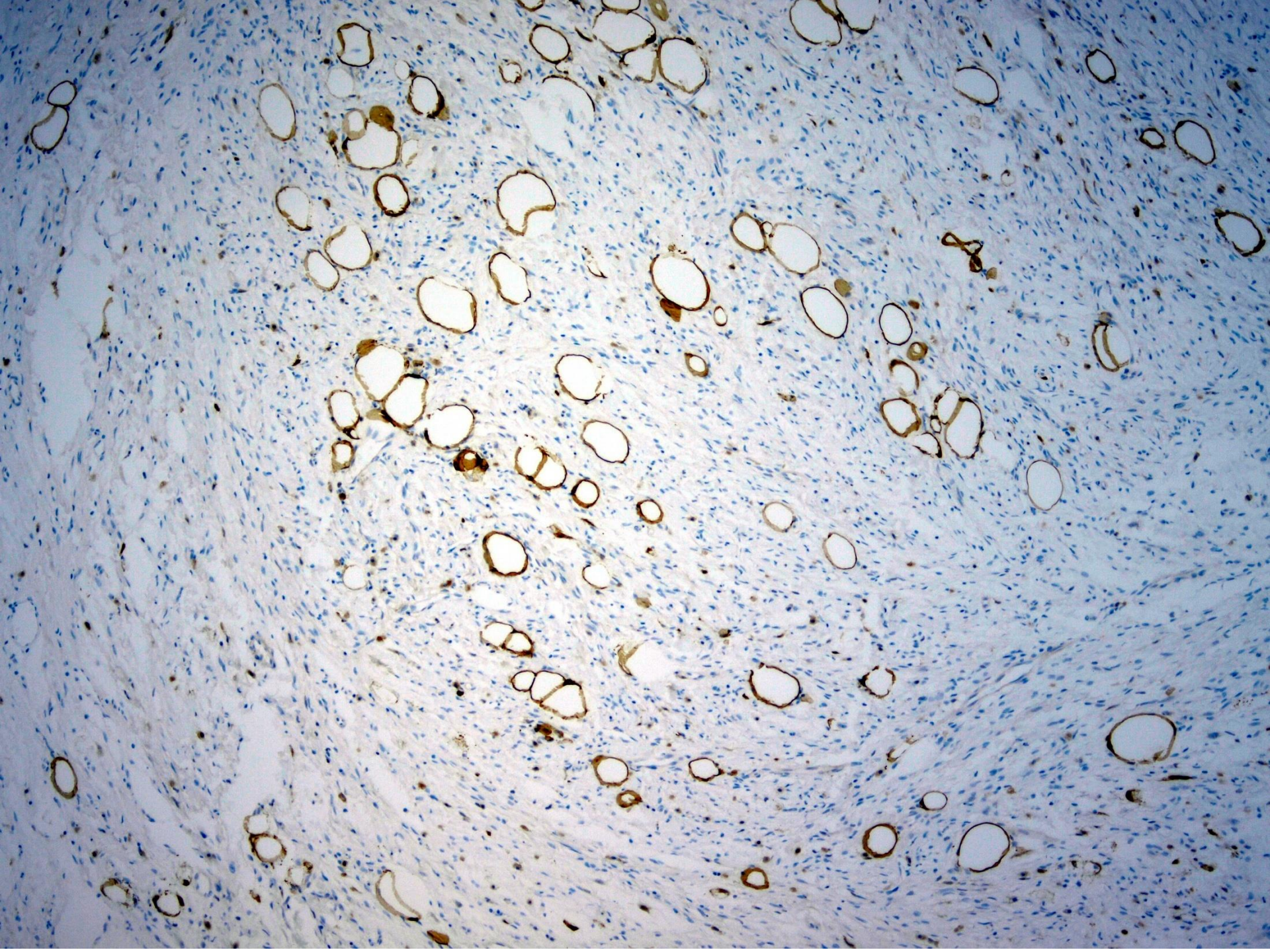

# MYXOINFLAMATÓRNY FIBROBLASTICKÝ SARKÓM (MIFS)

**Synonyms**

- Acral myxoinflammatory fibroblastic sarcoma
- Atypical myxoinflammatory fibroblastic tumor
- Inflammatory myxohyaline tumor of the distal extremities with virocyte or Reed-Sternberg-like cells

?

# HEMOSIDEROTICKÝ FIBROLIPOMATÓZNY TUMOR (HFLT)

?

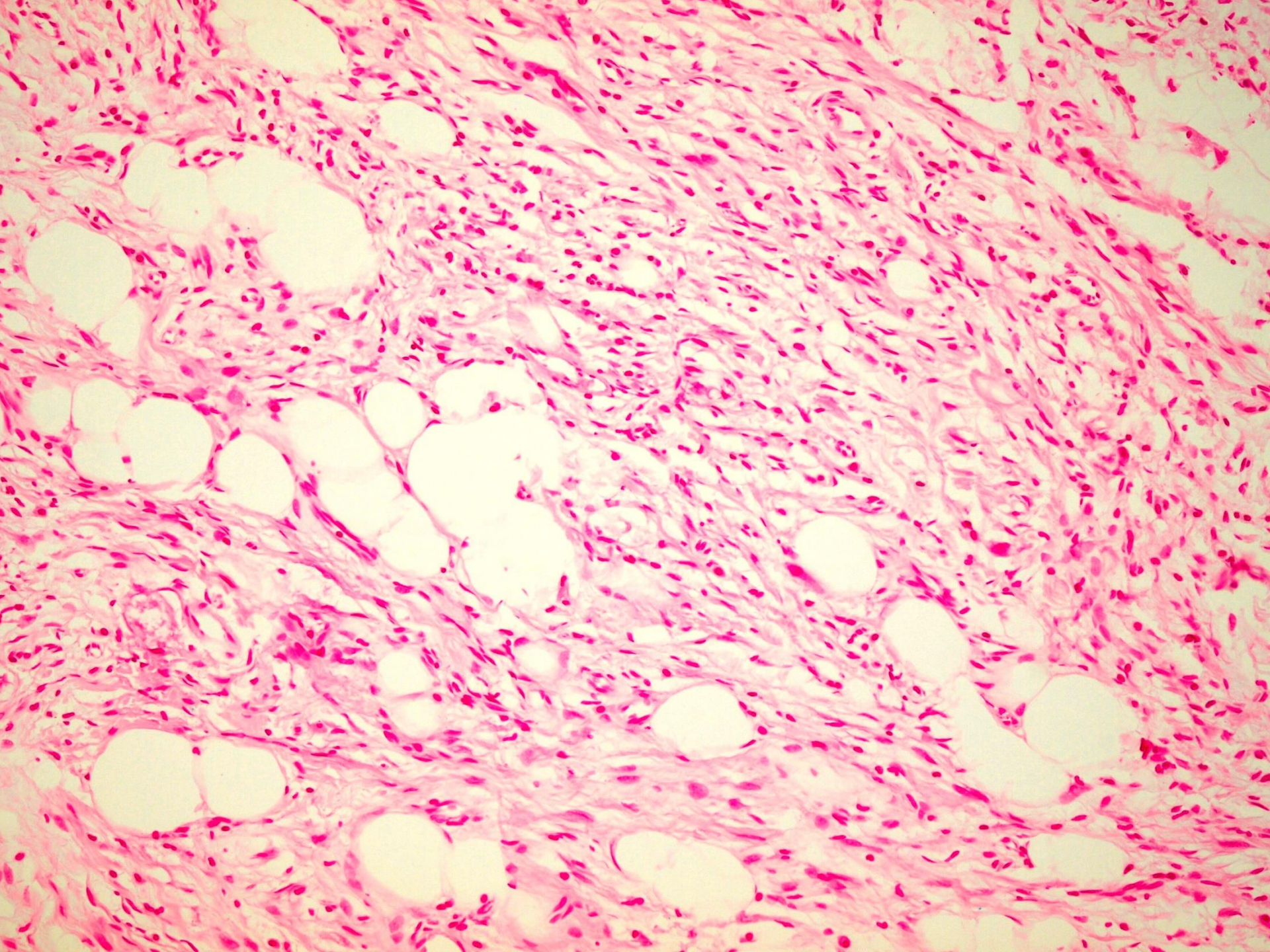

# HYBRIDNÝ MIFS/HFLT

# HFLT

# HFLT

- Lokálne agresívny, nemetastázujúci
- Mixtúra vretenovitých bb, zrelých adipocytov zväzky vretenovitých bb. periadipocytárne, perilobulárne
- F>M
- 40-60 r
- Recidíva v 50%
- Terapia chirurgická

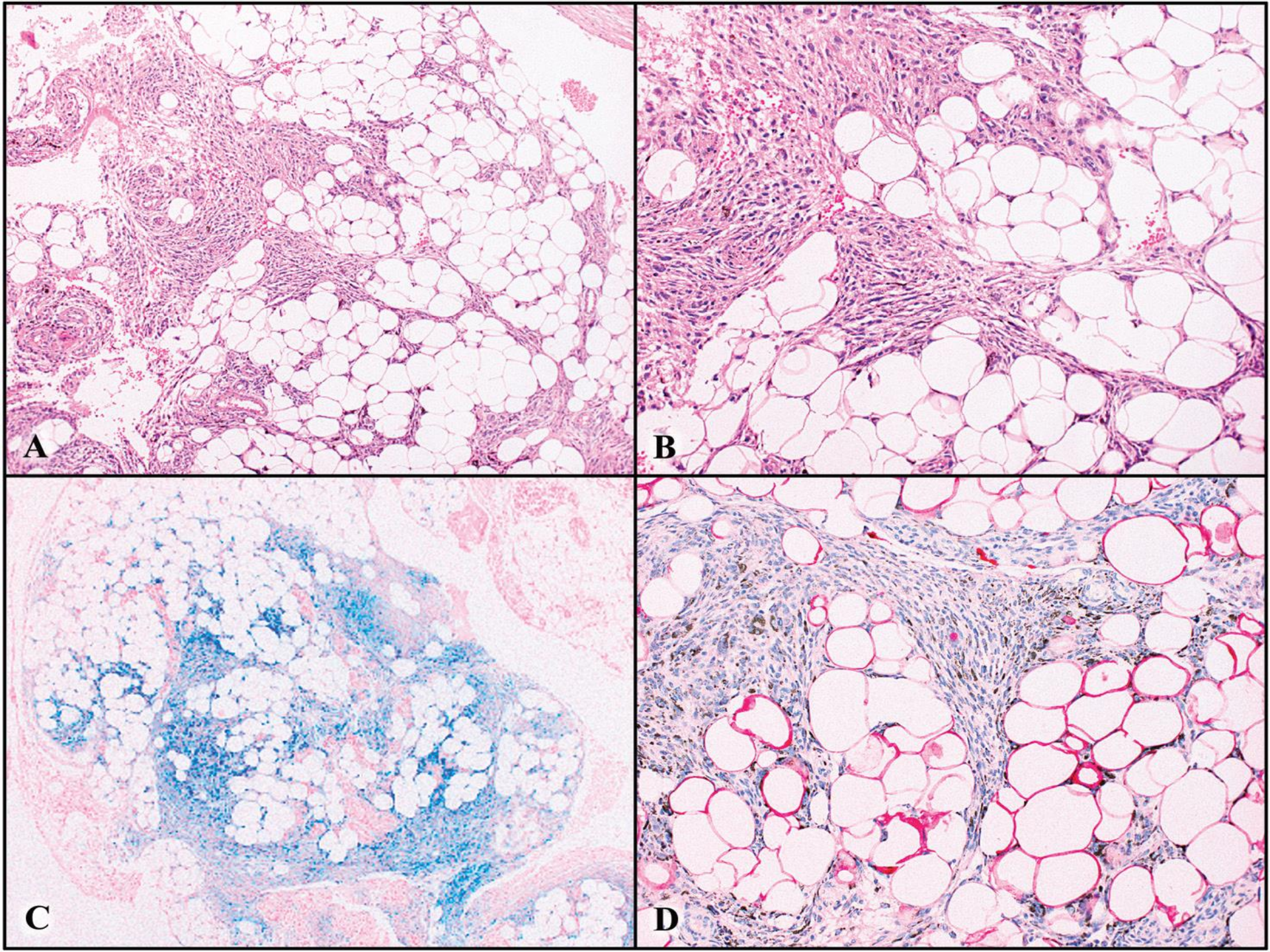
A
B
C
D

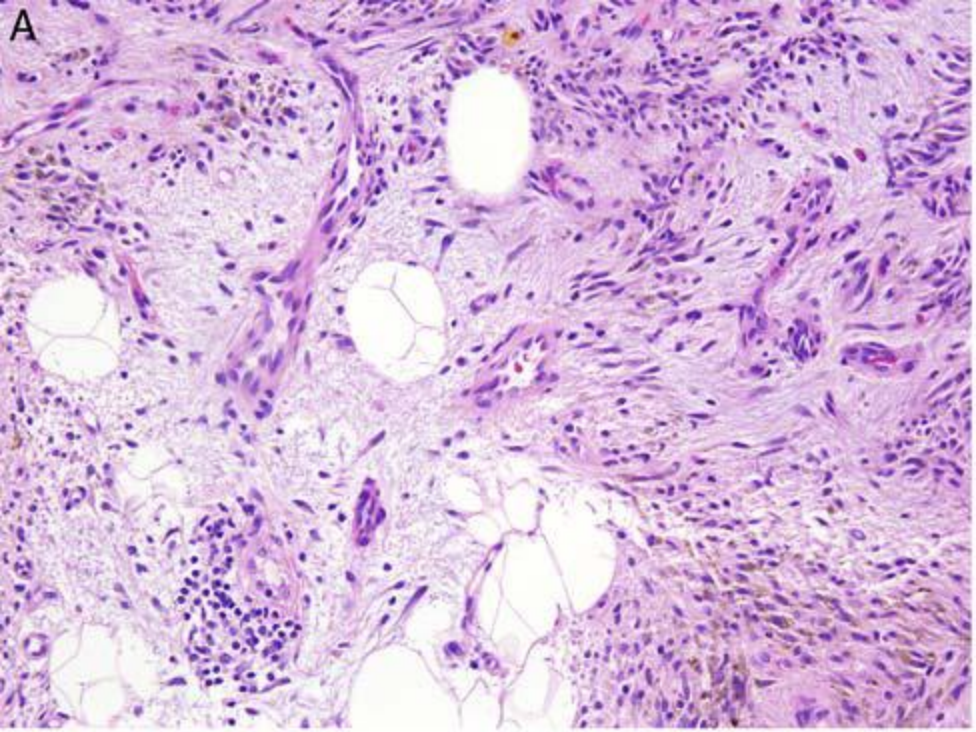


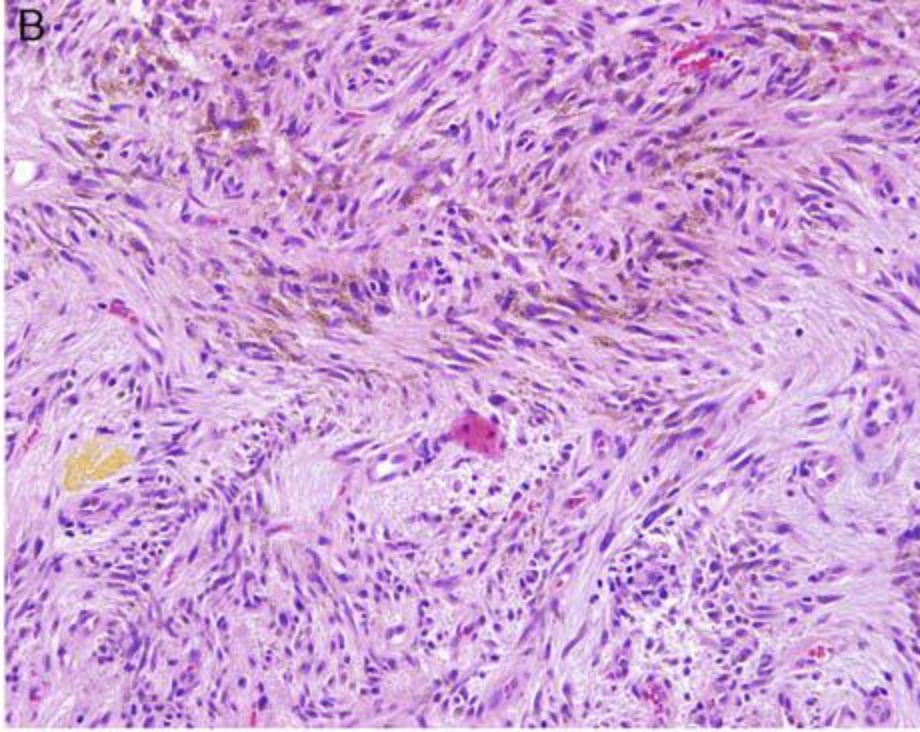


# HFLT

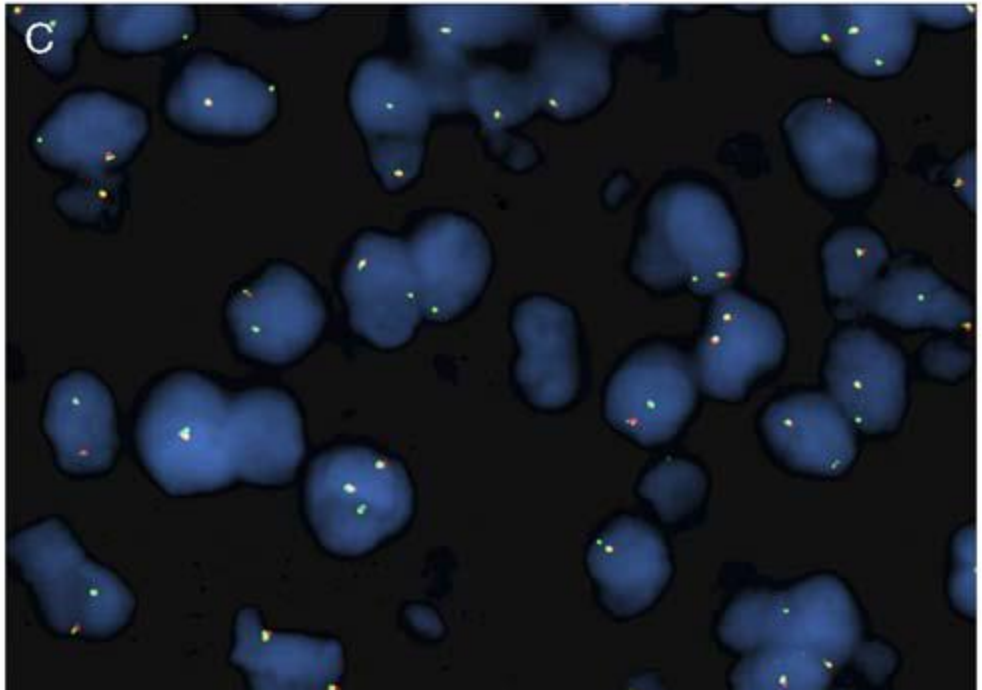


t(1;10)(p22;q24)

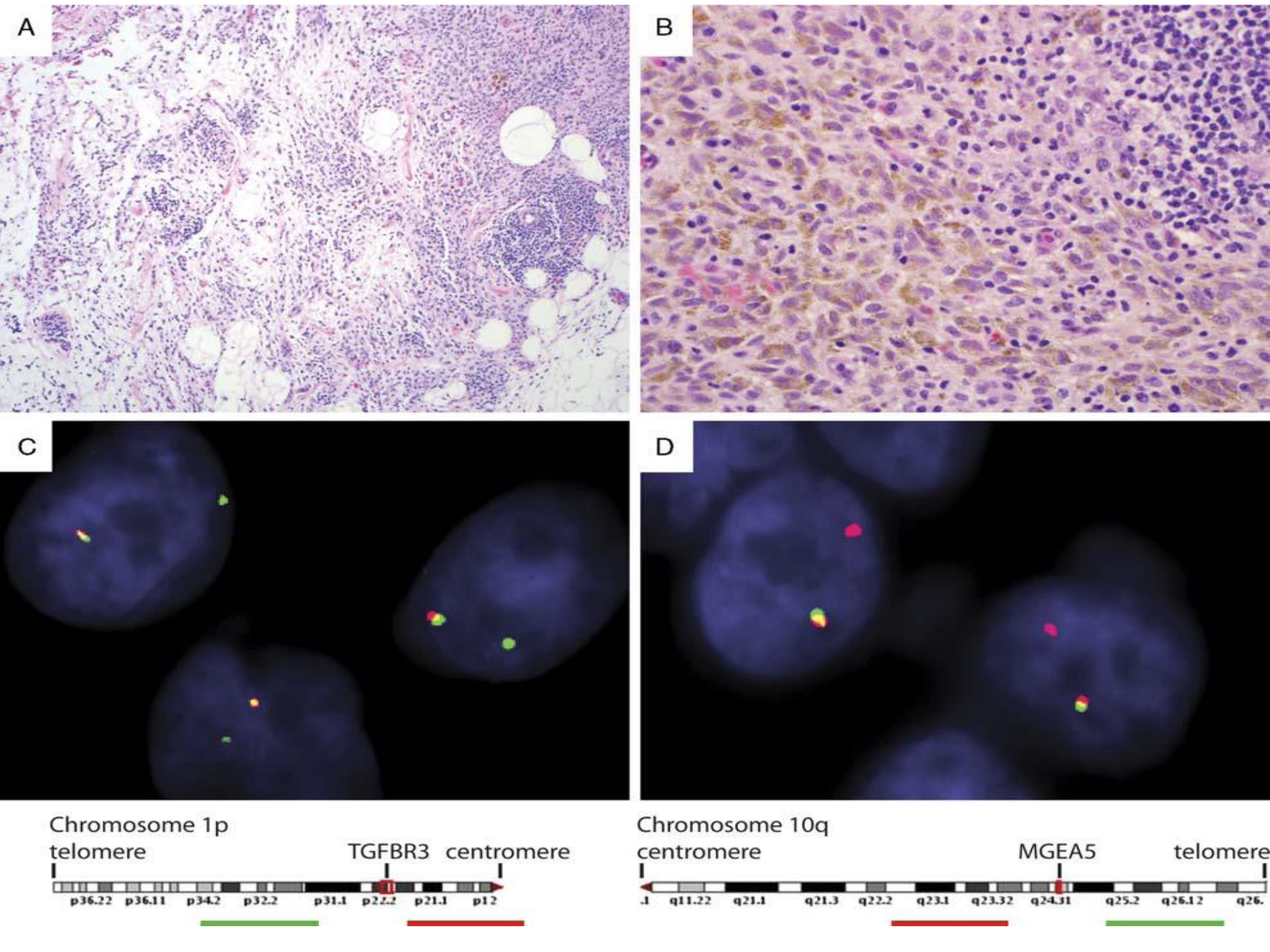
A
B
C
D
Chromosome 1p
telomere
TGFBR3
centromere
p36.22
p36.11
p34.2
p32.2
p31.1
p21.1
p12
Chromosome 10q
centromere
MGEA5
telomere
q11.22
q21.1
q21.3
q22.2
q23.1
q23.32
q24.31
q25.2
q26.12

# MIFS

- nádor fibroblastického/myofibroblastického pôvodu
- lokálne agresívny, zriedkavo mts (po lokorecidíve)
- extraakrálne je zriedkavý
- subkutánny, prerastá do svalu
- terapia chirurgická, radiačná

# MIFS

- multinodulárny, slabo ohraničený, infiltratívny
- 1-10 cm
- zóny myxoidné, hyalinizované, zápalové
- formácia germinálnych centier
- epiteloidné atypické bunky
- makronukleoly
- emperipoléza

# MIFS

- pseudolipoblasty
- OVB
- <5 mitóz/50 HPF
- celuárne zóny
- arkádovité kurvilineárne hrubostené cievy

# MIFS

- CD34, CD68, D2-40, CD117, EMA
- t(1;10)(p22;q24)
- Preskupenia of *TGFBR3* (1p22) a *MGEA5* (10q24)
- FISH analýza *TGFBR3 alebo MGEA5* majú diagnostické využitie

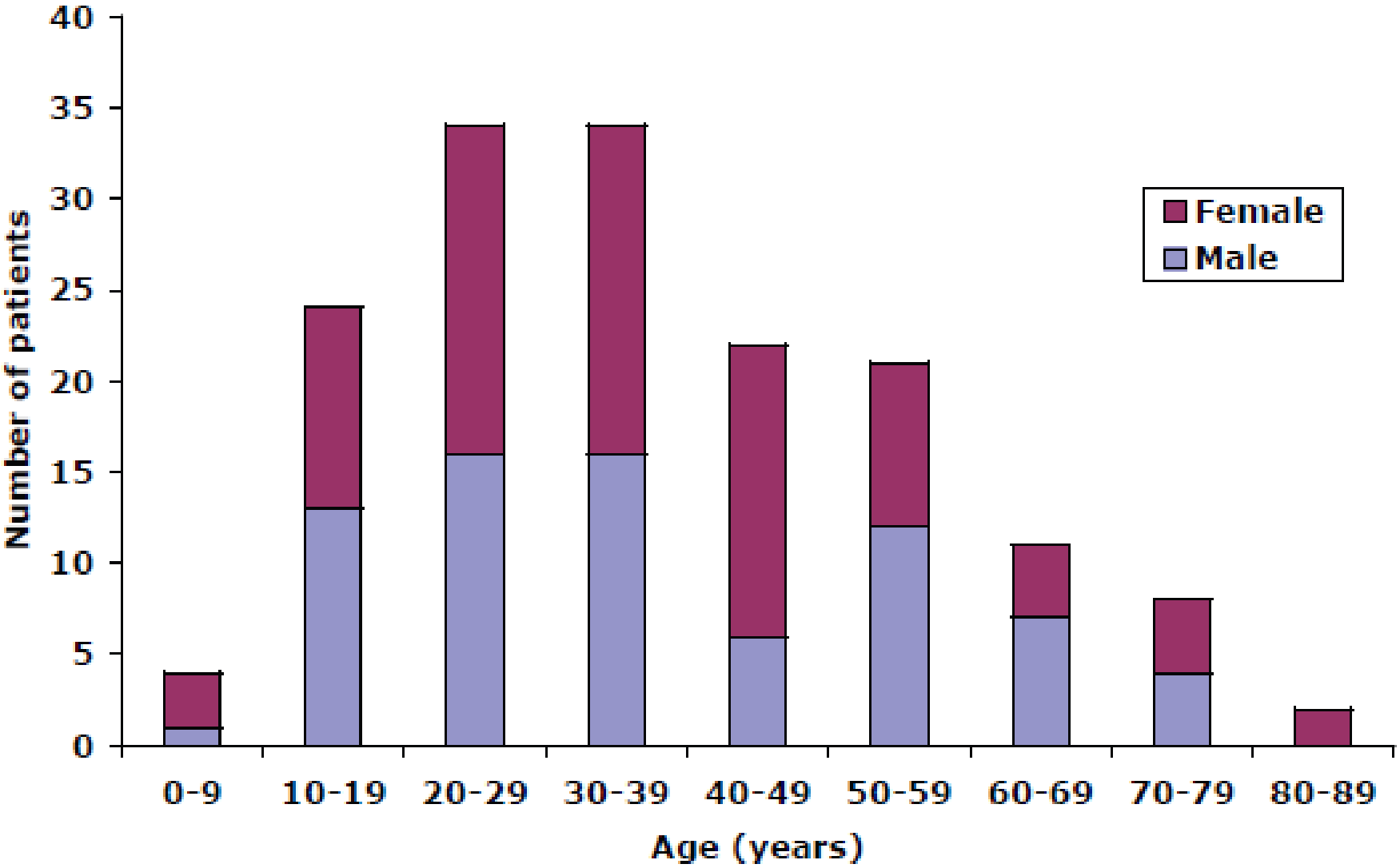
Number of patients
40
35
30
25
20
15
10
5
0
Female
Male
0-9
10-19
20-29
30-39
40-49
50-59
60-69
70-79
80-89
Age (years)

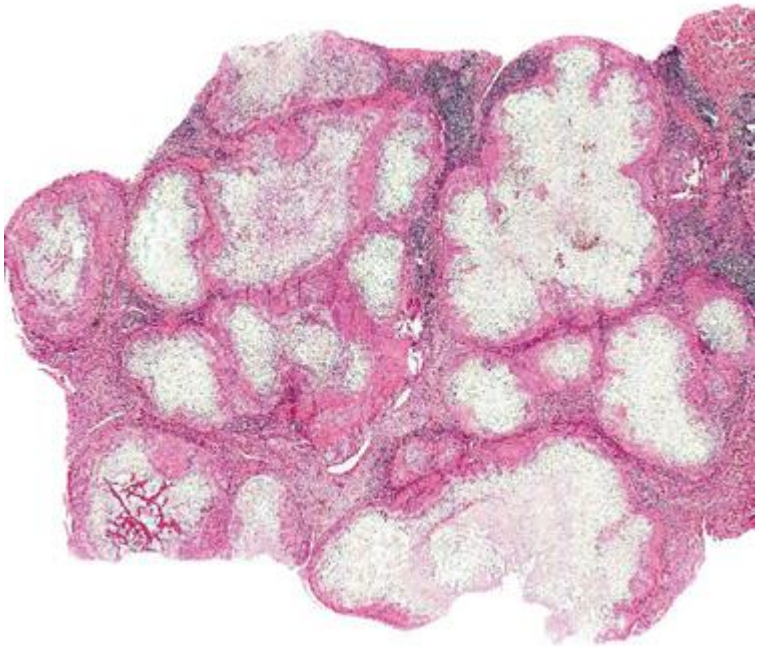

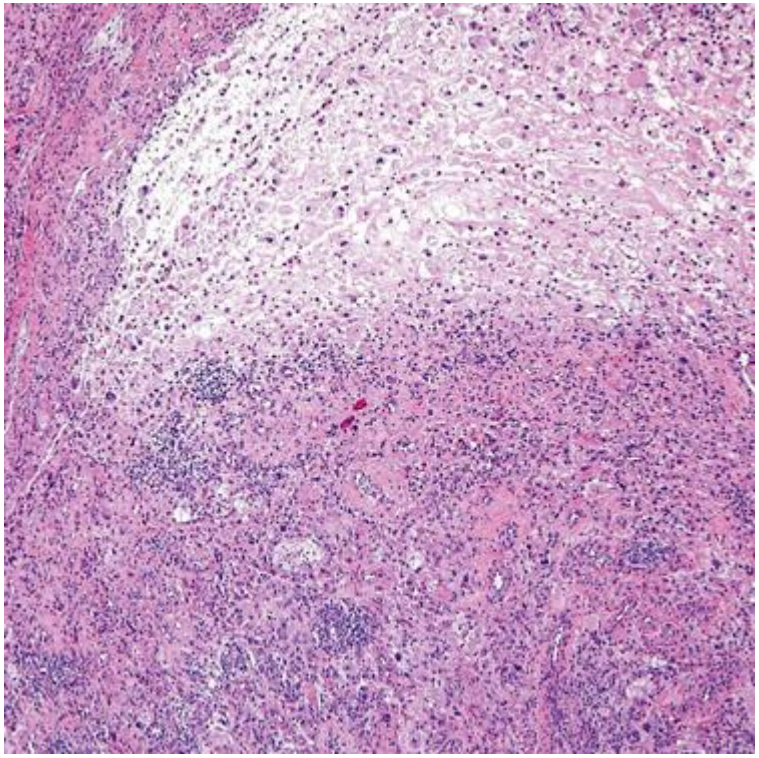

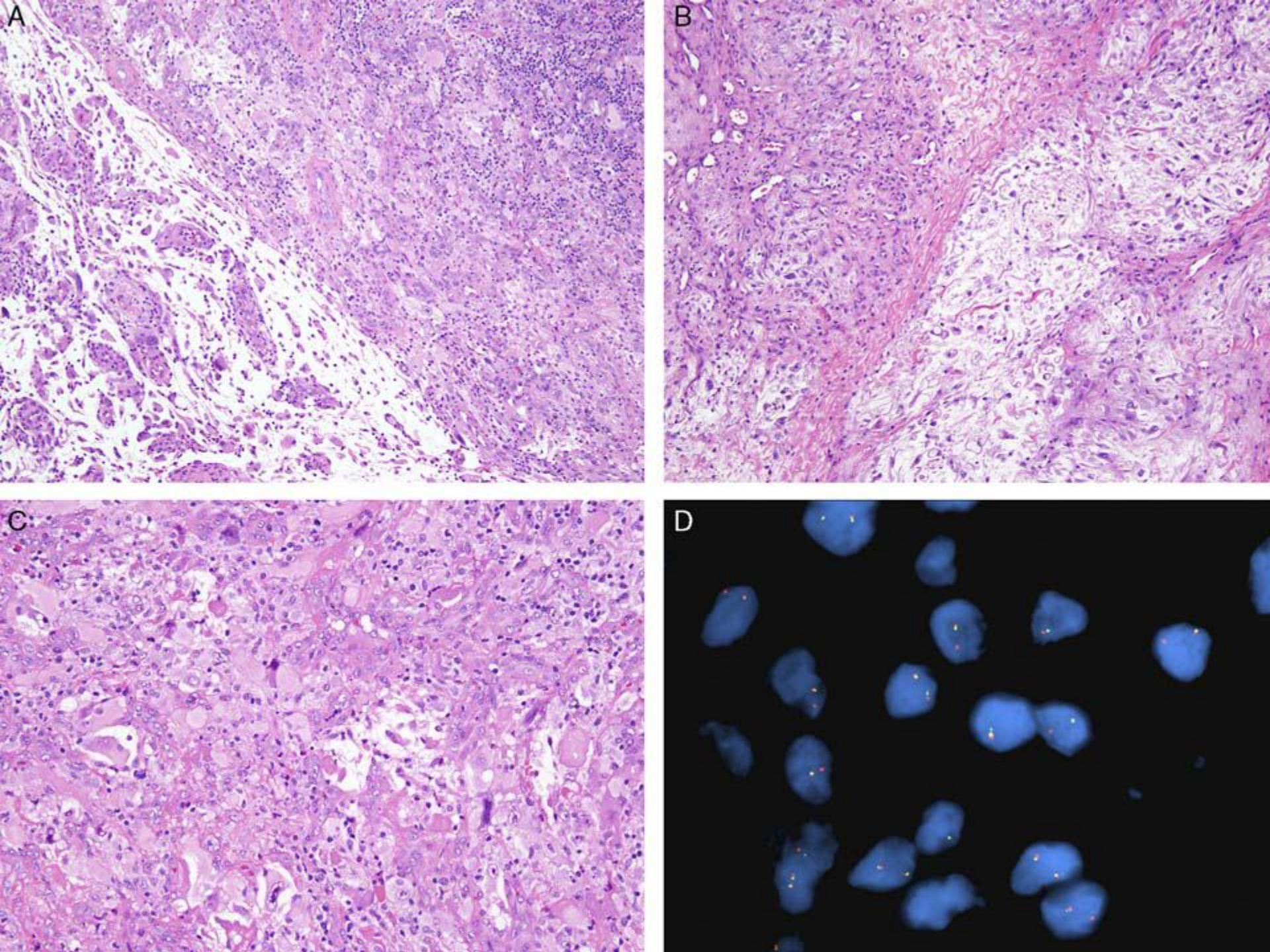
A
B
C
D

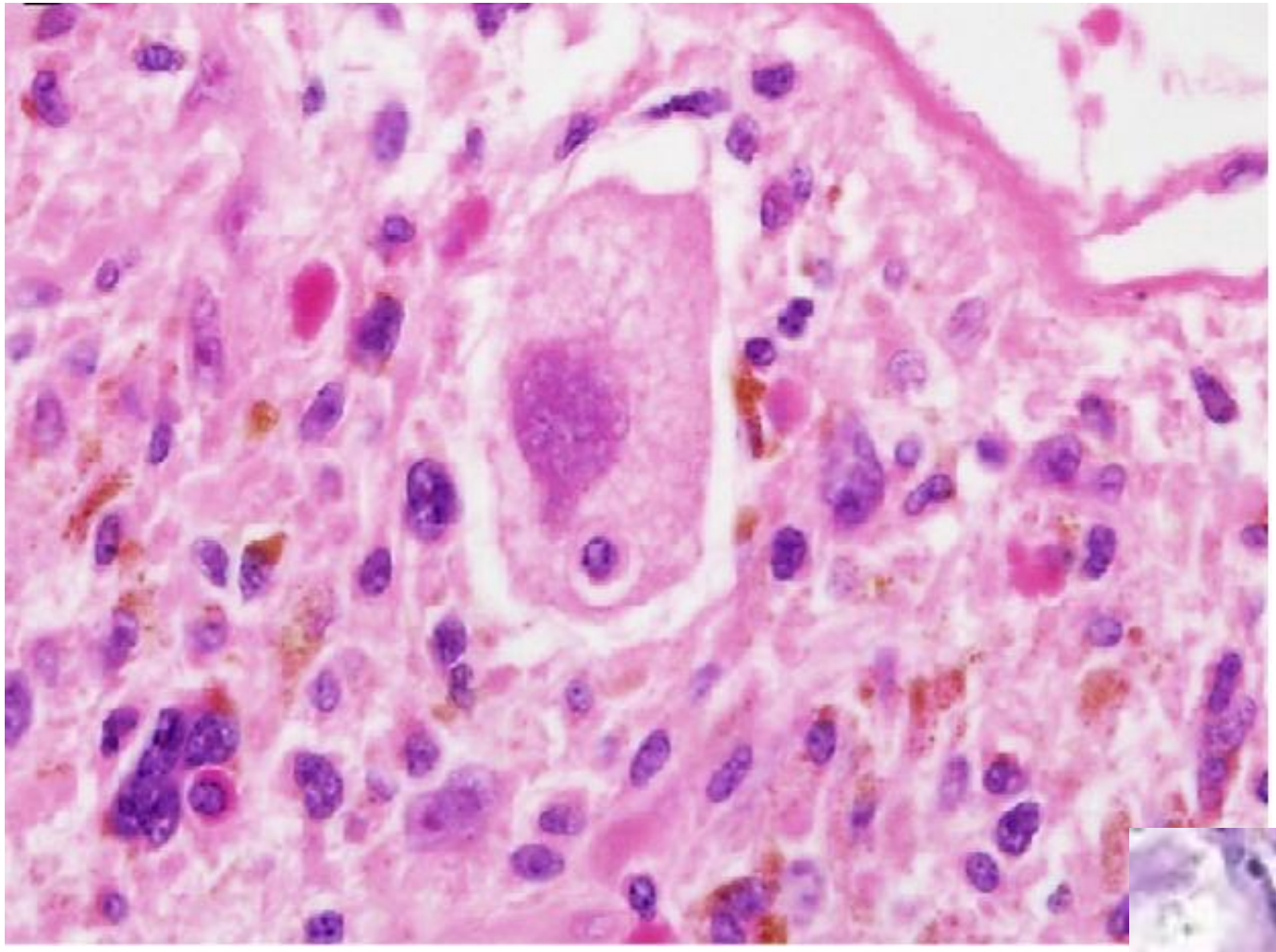

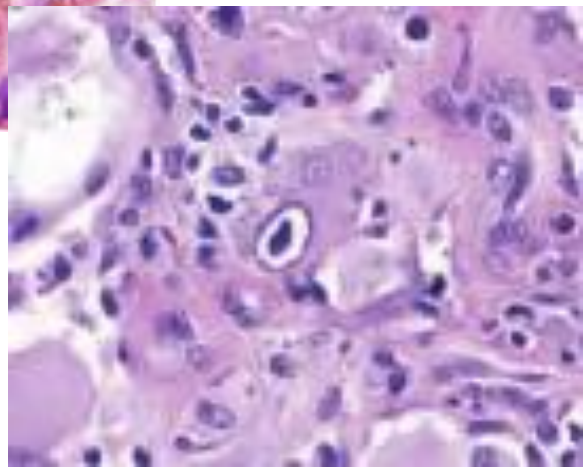

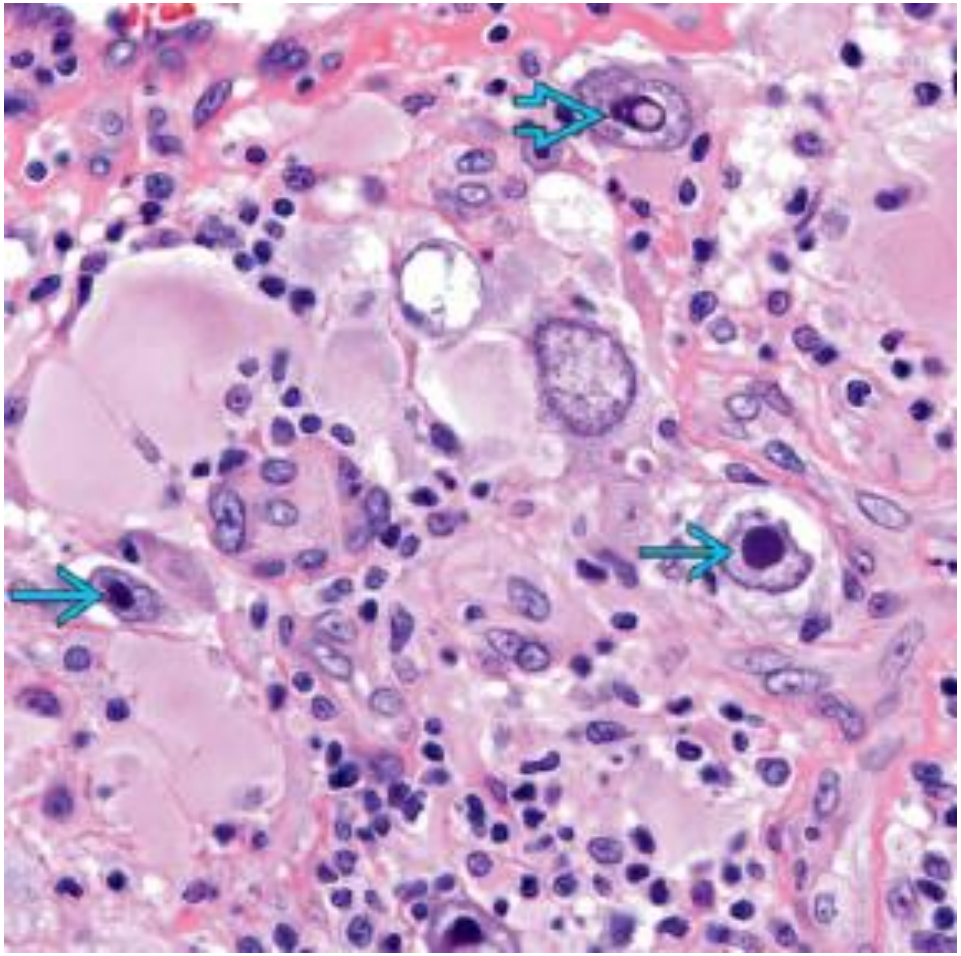

# t(1;10)(p22;q24)

- Identické preskupenia reportované v hybridných HFLT/MIFS

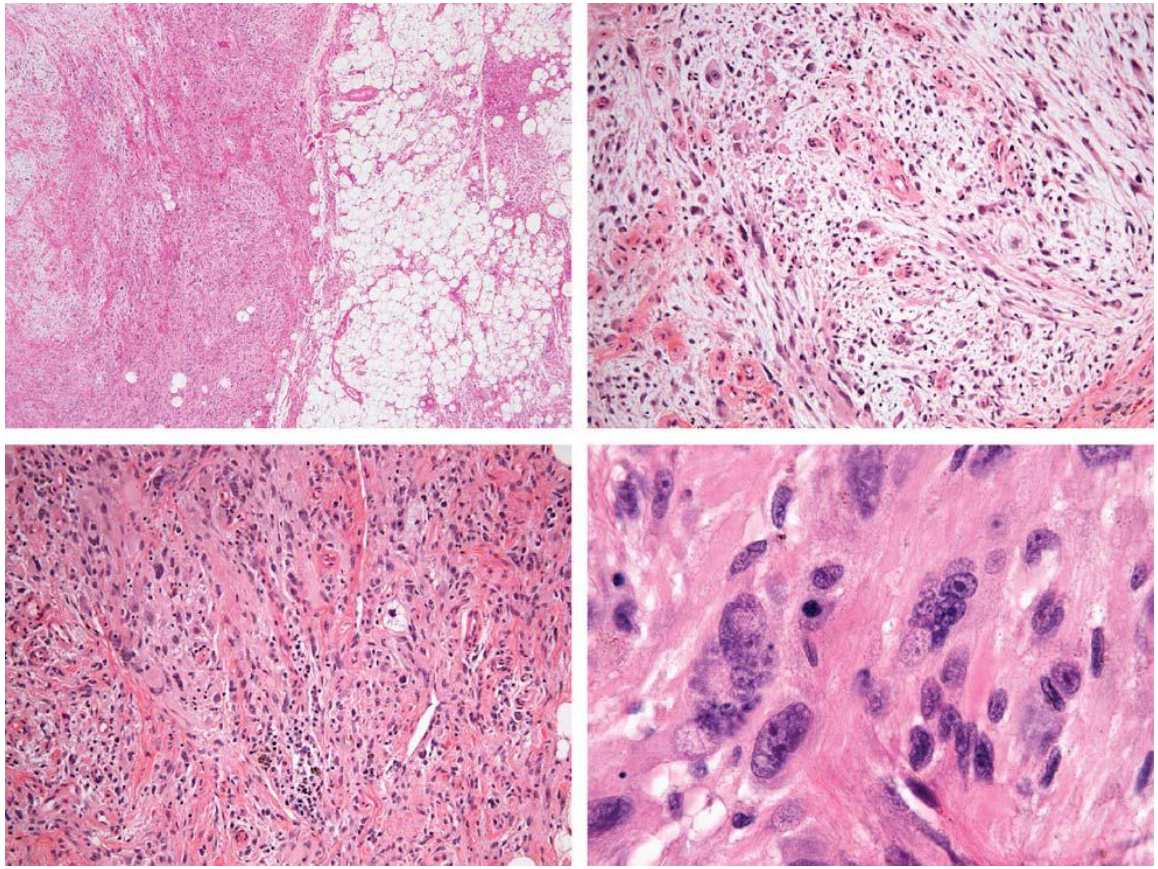

# PHAT

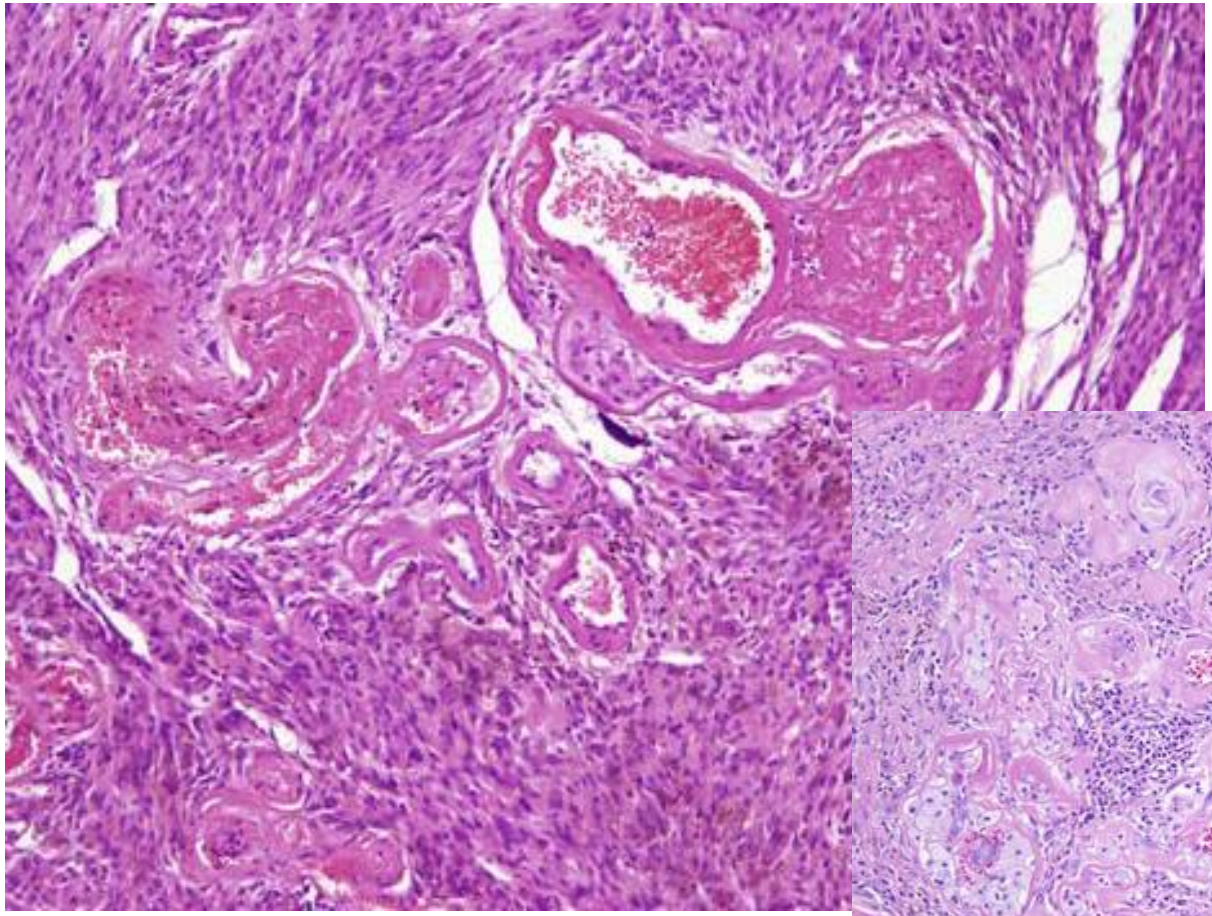

t(1;10)(p22;q24)

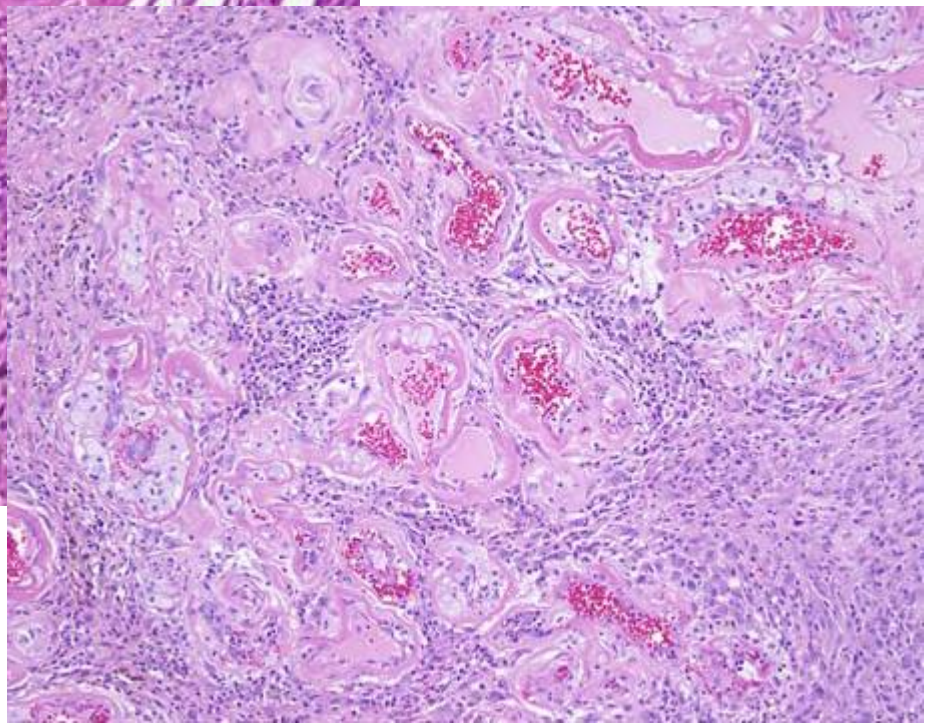

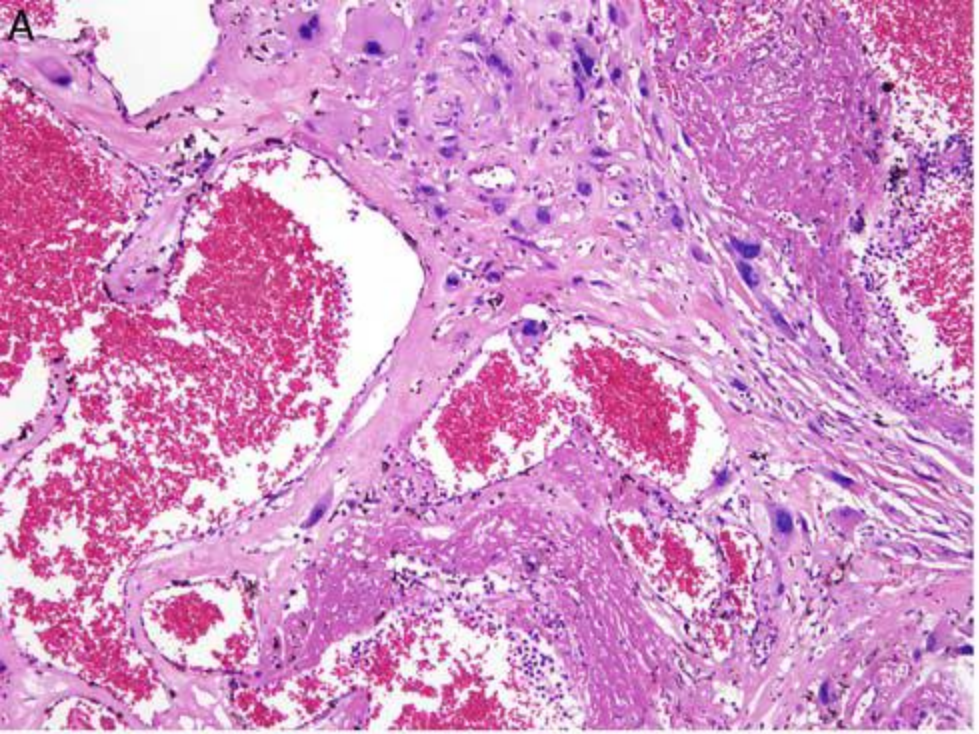


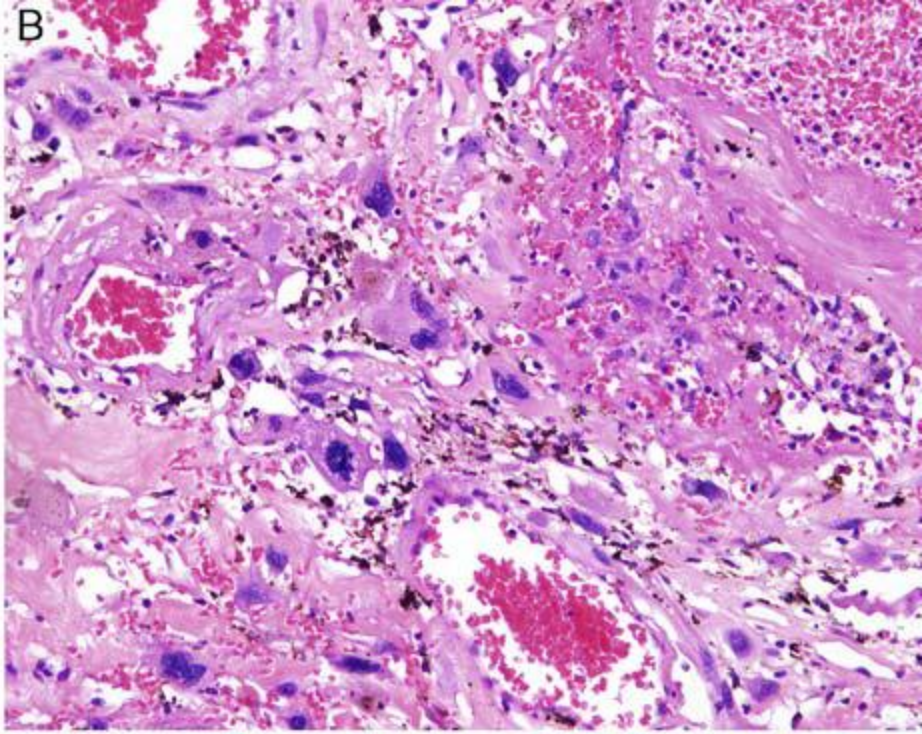


PS s PHAT like vaskulatúrou

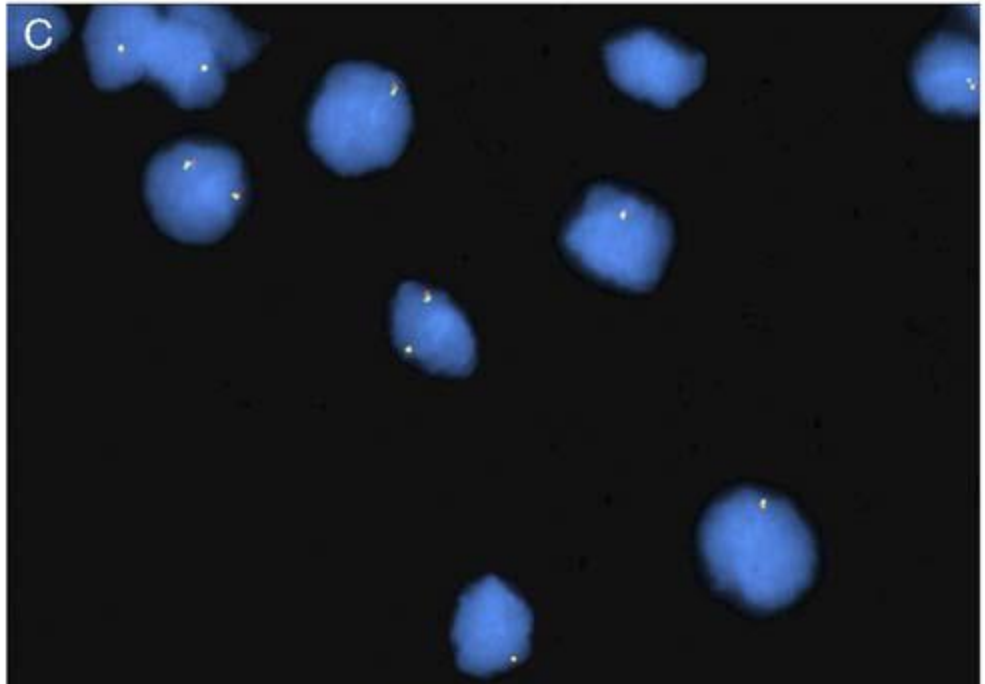

# Dif. dg.

- Vretenobunkový lipóm
- ALT
- m. Hodgkin
- Proliferatívna fascitída
- IMT
- MFS, DFSP
- Superficiálny CD34+ fibroblastický tumor

# Záver

1. Vzácny prípad tu mäkkých tkanív s črtami hybridného MIFS/HFLT vo veľmi nezvyčajnej lokalizácii, morfologický podobný ALT
2. MIFS, HFLT a PHAT reprezentujú pravdepodobne identickú biologickú entitu s rôznymi morfologickými prejavmi
3. **t(1;10)(p22;q24)**

# Literatúra


1. Lindberg MR. Diagnostic pathology. Soft tissue tumors. 2nd edition, 2015.
2. David A. Solomon et al. Hemosiderotic Fibrolipomatous Tumor, Not an Entirely Benign Entity. Am J Surg Pathol Volume 37, Number 10, October 2013.
3. Elco CHF et al. Hybrid Myxoinflammatory Fibroblastic Sarcoma/Hemosiderotic Fibrolipomatous Tumor: Report of a Case Providing Further Evidence for a Pathogenetic Link. Am J Surg Pathol 2010;34:1723–1727.
4. Carter JM et al. TGFBR3 and MGEA5 Rearrangements in
5. Pleomorphic Hyalinizing Angiectatic Tumors and the Spectrumof Related Neoplasms. Am J Surg Pathol 2014;38:1182–1992.